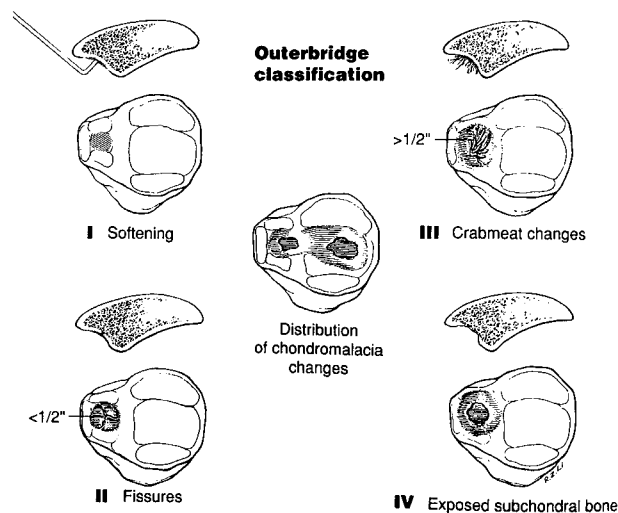


# Soft Tissue Problems of the Knee

Brian J. Cole, MD, Lucio S. Ernlund, MD and Freddie H. Fu, MD



**Figure 35-1** Outerbridge classification of chondromalacia. Grade I: softening and swelling. Grade II: fragmentation and fissuring in an area less than 1/2 inch. Grade III: the area is greater than 1/2 inch. Grade IV: cartilage erosion to bone. Reproduced with permission from Tria AJ, Klein KS. *An Illustrated Guide to the Knee*. New York, NY: Churchill Livingstone; 1992: 142.

35-1). It should not be used as a synonym for anterior knee pain or PF symptoms.

## ANTERIOR KNEE PAIN AND PATELLOFEMORAL DISORDERS

Patellofemoral (PF) disorders encompass a large differential diagnosis including but not limited to nonarthritic (non-PF) causes of anterior knee pain, PF malalignment, and PF arthritis. Diagnosis and treatment of non-PF causes of anterior knee pain is challenging. Patellofemoral malalignment and arthritis require accurate diagnosis to formulate a treatment plan. Rehabilitation focusing on the extensor mechanism, when unsuccessful, may lead to one of several realignment-type procedures. The term chondromalacia patella as described by Outerbridge (1961) describes the pathologic changes often occurring concomitantly with PF pain (Fig.

### PITFALL

Chondromalacia is often used as a synonym for anterior knee pain and should only be used when describing the gross pathology of the articular cartilage.

### Basic Science Biomechanics

Normal function of the PF joint depends on the balance between lower extremity alignment as well as static (retinaculum, bony anatomy, Q [quadriceps] angle) and dynamic

2. distal: patellar tendon
3. medial: VMO, retinaculum and PF ligament
4. lateral: vastus lateralis tendon, retinaculum, and iliotibial band (ITB)

The medial PF ligament is the major restraint to lateral displacement (53%). Capsular thickenings, called patellomeniscal ligaments (Kaplan's ligaments), are thought to be the cause of referred joint line pain in PF disorders.

### *Vascular and Arterial Supply*

Circumferential anastomoses of the four genicular, the supreme genicular, and the medial and anterior tibial recurrent arteries comprise the majority of the arterial supply. Venous drainage is by the popliteal and internal saphenous veins.

### *Innervation*

Nocioceptive pain fibers within the lateral retinaculum are believed to be a cause of anterior and PF knee pain.

## **Examination**

### *History*

#### *Mechanism*

Ask the patient about specific patellar trauma, subluxation, or dislocation.

#### *Pain*

Patients with PF disorders often have poorly localized dull ache exacerbated by prolonged sitting ("movie sign") or stair climbing. This is often bilateral and of insidious onset. Locations most commonly include anteromedial, retropatellar, and posterior. Pain in long-standing PF disease may be from soft tissue contractures, lateral retinacular pain fibers, and arthrosis.

#### *Giving Way*

Patellofemoral "giving way" may represent patellar instability or occur secondary to painful quadriceps inhibition unlike that which occurs secondary to ligamentous instability where the knee "comes apart."

#### *Crepitus*

Crepitus is often bothersome to the patient, not commonly associated with pain, and not to be overtreated. Sources include malalignment, synovial impingement, quadriceps tendon, and chondrosis.

#### *Locking*

A patient may have a catching sensation that occurs during extension under load (stair-climbing or chair-rising), unlike meniscal pathology where the knee "locks up."

#### *Swelling*

Swelling is less common in PF disorders. It suggests intra-articular pathology. Peripatellar soft tissue swelling can also occur.

## **PEARL**

**Bilateral complaints of pain of insidious onset exacerbated by prolonged sitting with the knee in a flexed position or while negotiating stairs is relatively common in PF disease.**

### *Physical Examination*

In addition to tests specific for PF disorders (below), the exam should include tests necessary to establish other pathologic conditions that may exist.

#### *Observation*

Evaluate for foot pronation, external tibial torsion, genu valgum, femoral anteversion (hip internal rotation) and valgus, gynecoid pelvis, flexion contractures, patellar subluxation and Q angle measured in extension and flexion.

#### *Palpation*

##### **Effusion**

Use distally directed pressure on the suprapatellar area with the palm of one hand while balloting the patella medially with the other hand.

##### **Tenderness**

Palpate for tenderness in all anterior knee structures including entire extensor mechanism, medial/lateral patellar facets, retinaculum, epicondyles, ITB, pes anserinus, joint line, and fat pad.

##### **Flexibility and Strength**

Evaluate quadriceps (prone knee flexion), hamstrings (supine popliteal angles), and ITB for abnormal flexibility and strength.

##### **Crepitus**

Apply posteriorly directed patellar pressure during active and passive range of motion (ROM). Note the presence of pain and where in the flexion arc it occurs.

##### **Percussion**

Evaluate for neuromas at prior surgical sites.

#### *Special Tests*

##### **Lateral Pull Sign**


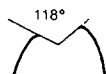
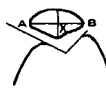
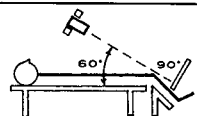
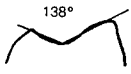

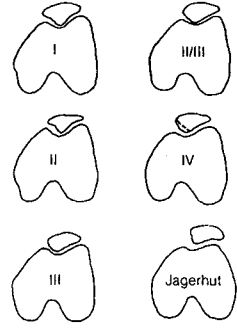
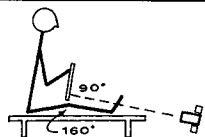




Test for VMO insufficiency leading to disproportionate superolateral pull of the patella with quadriceps contraction with the knee in extension.

##### **J Sign**

Persistent lateral patellar movement with flexion (J sign) rather than inferomedial may occur with PF malalignment.

##### **Extensor Lag**

Passive range of motion (PROM) greater than active range of motion (AROM) is consistent with quadriceps insufficiency.

TANGENTIAL VIEW	KNEE FLEXION	TECHNIQUE AND POSITION	MEASUREMENTS	MISCELLANEOUS
Hughston	55 degrees	 <p>Prone position. Beam directed cephalad and inferior, 45 degrees from vertical.</p>	1) Sulcus angle: $118^\circ$  2) Patella index: $\frac{AB}{XB - XA}$ NL: Male 15 Female 17 	<ul style="list-style-type: none"> <li>Patellar dislocation</li> <li>Osteochondral fracture</li> <li>Soft tissue calcification (old dislocated patella or fracture)</li> <li>Patellar subluxation</li> <li>Patellar tilt</li> <li>Increased medial joint space</li> <li>Apex of patella lateral to apex of femoral sulcus</li> <li>Lateral patella edge lateral to femoral condyle</li> <li>Hypoplastic lateral femoral condyle (usually proximal)</li> </ul>
Merchant	45 degrees	 <p>Supine position. Beam directed caudal and inferior, 30 degrees from vertical.</p>	1) Sulcus angle: $138^\circ$  2) Congruence angle: 	<ul style="list-style-type: none"> <li>Patellofemoral osteophytes</li> <li>Subchondral trabeculae orientation (increase or decrease)</li> <li>Patellar configuration (Wiberg-Baugart)</li> </ul> 
Laurin	20 degrees	 <p>Sitting position. Beam directed cephalad and superior, 160 degrees from vertical.</p>	1) Lateral patellofemoral angle: NL:  ABNL:  ABNL:  2) Patellofemoral index: Ratio A/B Normal = 1.6 or less 	

**Figure 35-5** Patellofemoral (PF) measurements on plain tangential radiographs. Reproduced with permission from Carson WG et al. Patellofemoral disorders; physical and radiographic evaluation. Part I: physical examination. *Clin Orthop.* 1984;185:126.

tilt is best demonstrated at 20 to 30 degrees using Laurin's view. Subluxation decreases from 0 to 30 degrees of flexion and is best measured using the Mercer-Merchant view at 45 degrees flexion. Lateral facet arthrosis is seen as subchondral sclerosis, cyst formation, perpendicular trabeculae, facet collapse, lateral margin patellar osteophytes, or fractures and calcification within the lateral retinaculum. Medial facet osteoporosis may be present from relative unloading.

**Sunrise View**


In this view, the knee is flexed 60 to 90 degrees and the beam is tangential to the PF joint. One can see more of the femoral condyles than on other to views described below. The sunrise view is good for patellar fractures, dislocations, loose bodies and articular irregularities but not for malalignment measures.

**Mercer-Merchant View**

The knee is flexed 45 degrees, and the X-ray is angled caudad 30 degrees in this view (Fig. 35-6). The sulcus angle (Normal: 140 degrees  $\pm$  5 degrees) and the congruence angle (Normal: -6 degrees  $\pm$  11 degrees) are formed between lines bisecting the sulcus and median crest, reflecting patellar centralization and/or subluxation. Normally, the median crest bisector (solid line) is medial to the sulcus bisector (broken line) and is considered negative by convention. A congruence angle greater than 16 degrees is diagnostic of lateral subluxation.

**Laurin View**

This is a 20-degree tangential view. The lateral PF tilt angle is the intersection of the line connecting the peaks of the femoral



**Figure 35-6** A typical Merchant's view suggesting lateral patellar subluxation. Only the anterior one-third of the condyles are imaged compared to a sunrise view demonstrating most of the femur. Note lateral subluxation and tilt of the left patella.

*Patellar Osteochondritis Dissecans*

This condition rarely may occur along the lateral facet. It is diagnosed best by lateral and axial radiographs. Treatment is determined by the stage of the lesion, including immobilization or drilling (stage I), drilling and fixation (stages II and III), and abrasion chondroplasty with excision (stage IV).

*Saphenous Neuralgia and Varices*

The inferomedial arthroscopic portal or trauma may damage the infrapatellar branch of the saphenous nerve or peripatellar tissues. Patients complain of numbness or burning along the anterior knee that remains symptomatic at rest. Discrete tenderness is relieved by injection of 1% lidocaine (Xylocaine). Neuroma excision is usually curative. Anterior saphenous varices present with activity-related swelling about the medial side of the knee that decreases with elevation. Vascular consultation and ligation may be curative.

*Cruciate Ligament Insufficiency*

Cruciate insufficiency, treated conservatively or with reconstruction, may present with anterior knee pain. Some reports on the use of hamstring rather than patellar tendons for anterior cruciate ligament (ACL) reconstruction have demonstrated decreased rates of PF pain.

*Adolescent Anterior Knee Pain*

This is a broad category and includes PF malalignment, excessive lateral compression syndrome, patella alta/baja, muscle imbalance, Sinding-Larssen-Johanssen disease, Osgood-Schlatter's disease, and hypermobility of the patella secondary to excessive ligamentous laxity. Most of these conditions are treated with conservative modalities (i.e., physical therapy and relative rest) and rarely require surgery.

*Reflex sympathetic dystrophy*

Patients with reflex sympathetic dystrophy have histories of trauma leading to severe anterior knee pain even at rest, atrophy, skin changes (shiny, red, warm, alopecia) and symptoms out of proportion to the inciting event. Radiographs may show diffuse osteopenia. Bone scans show a "hot" PF joint. Treatment includes desensitization, physical therapy, and sympathetic blockade.

*Patellofemoral Disorders*

The term patellar instability is specific to patients with a history of lateral subluxation or dislocation, but it may also include patients with ELCS. Articular damage is a common sequelae of long-standing tilt and recurrent instability. A history of trauma, effusion, and crepitus with reproduction of symptoms with PF compression is common.

Operative treatment assumes that at least 3 months of nonoperative treatment have failed. Treatment of PF instability includes lateral release (LR), proximal realignment, and medial tubercle transfer. Treatment of articular degeneration includes chondroplasty, tubercle elevation, patellectomy, and arthroplasty. In general, tubercle elevation reduces sagittal plane forces; and LR, proximal realignment, and medialization of the tubercle reduces coronally directed forces. Combinations of the above procedures should be utilized when appropriate.

*Excessive Lateral Compression Syndrome  
(isolated patellar tilt)***Definition**

The definition of ELCS is chronic lateral tilt and compression of the patella from lateral retinacular tightness without instability, hypermobility, or abnormal Q angle.

**History**

The patient will have a history of activity-related bilateral anterior knee pain with stairs or sitting.

**Physical Findings**

On examination one finds negative patellar tilt, decreased medial patellar glide, loss of flexibility, facet and retinacular tenderness, positive lateral pull and J signs.

**Radiologic Findings**

Radiologic workup shows abnormal lateral PF tilt angle, normal or nearly normal congruence angle, and patellar arthrosis.

**Treatment**

Treatment comprises arthroscopy, chondral debridement, and LR. High-grade arthrosis may require additional antero-medialization of the tubercle.

*Patellar Instability***Definition**

Patellar instability is a spectrum ranging from patellar subluxation to frank dislocation.

**History**

There will be a history of patellar slipping with cutting maneuvers and a possible history of trauma.

**Physical Findings**

Apprehension, increased lateral patellar glide, and negative patellar tilt with lateral retinacular tightness are often present.

**Radiologic Findings**

Abnormal congruence angle and abnormal lateral PF angle with tilt are found.

**Treatment**

Treatment comprises LR only with normal alignment; medial tubercle transfer with evidence of malalignment and low-grade arthrosis. High-grade arthrosis requires anteromedialization of the tubercle.

*Patellar Arthrosis***Definition**

Varying degrees of arthritis due to trauma and/or malalignment define patellar arthrosis.

**History**

There will be a history of pain primarily with stairs and extension and, possibly, a remote history of trauma.

# Soft Tissue Problems of the Knee

Brian J. Cole, MD, Lucio S. Ernlund, MD and Freddie H. Fu, MD

## Outline

### Anterior Knee Pain and Patellofemoral Disorders

Basic Science  
Anatomy  
Examination  
Aids to Diagnosis  
Specific Conditions, Treatment, and Outcome

### Anterior Cruciate Ligament Injuries

Basic Science  
Anatomy  
Examination  
Aids to Diagnosis  
Specific Conditions, Treatment, and Outcome

### Posterior Cruciate Ligament Injuries

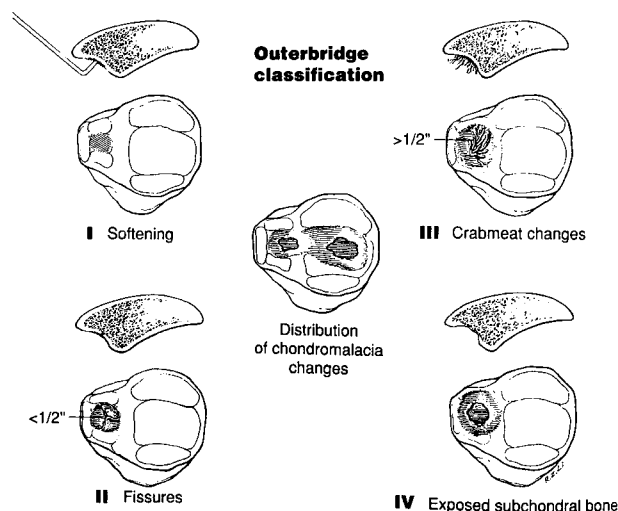
Basic Science  
Anatomy  
Examination  
Aids to Diagnosis  
Specific Conditions, Treatment, and Outcome

### Meniscal Injuries

Basic Science  
Anatomy  
Examination  
Aids to Diagnosis  
Specific Conditions, Treatment, and Outcome

### Selected Bibliography

### Sample Questions



**Figure 35-1** Outerbridge classification of chondromalacia. Grade I: softening and swelling. Grade II: fragmentation and fissuring in an area less than 1/2 inch. Grade III: the area is greater than 1/2 inch. Grade IV: cartilage erosion to bone. Reproduced with permission from Tria AJ, Klein KS. *An Illustrated Guide to the Knee*. New York, NY: Churchill Livingstone; 1992: 142.

35-1). It should not be used as a synonym for anterior knee pain or PF symptoms.

## ANTERIOR KNEE PAIN AND PATELLOFEMORAL DISORDERS

Patellofemoral (PF) disorders encompass a large differential diagnosis including but not limited to nonarthritic (non-PF) causes of anterior knee pain, PF malalignment, and PF arthritis. Diagnosis and treatment of non-PF causes of anterior knee pain is challenging. Patellofemoral malalignment and arthritis require accurate diagnosis to formulate a treatment plan. Rehabilitation focusing on the extensor mechanism, when unsuccessful, may lead to one of several realignment-type procedures. The term chondromalacia patella as described by Outerbridge (1961) describes the pathologic changes often occurring concomitantly with PF pain (Fig.

### PITFALL

Chondromalacia is often used as a synonym for anterior knee pain and should only be used when describing the gross pathology of the articular cartilage.

### Basic Science

#### Biomechanics

Normal function of the PF joint depends on the balance between lower extremity alignment as well as static (retinaculum, bony anatomy, Q [quadriceps] angle) and dynamic

vastus medialis obliquus (VMO) stabilizers. The patella increases the moment arm (the distance between the extensor mechanism to the center of the knee) and thereby increases quadriceps strength by one third to one half. Large forces are generated across the PF joint:

- walking:  $0.5 \times$  body weight
- stair climbing:  $3.3 \times$  body weight
- deep squats:  $7 \times$  body weight

The lateral and inferior articular surfaces normally contact the trochlea at 10 to 20 degrees of flexion. As flexion increases, the contact site moves medial (45 degrees) and proximal (90 degrees) with the odd facet coming into contact last (135 degrees). With patella alta, sites of contact occur at higher degrees of flexion.

Coronal (lateral) plane contact forces are greatest at low flexion angles ( $< 30$  degrees). In general, sagittal (posterior) plane PF contact forces increase with knee flexion between 0 degrees and 90 degrees. These increases are partly mitigated by increasing PF contact area at higher flexion angles (pressure = force/area). Normally, after 90 degrees, the quadriceps tendon contacts the trochlea, resisting increases in PF contact pressure. Patellofemoral contact pressures vary with testing conditions. During open-chain (nonweight-bearing) extension exercises, the flexion moment arm increases and PF contact pressure peaks at terminal extension. During closed-chain exercises (weight-bearing), PF contact pressure peaks as the flexion angle increases.

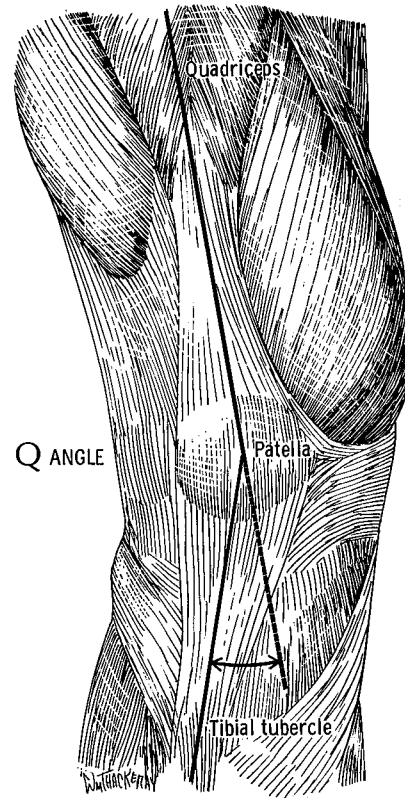
### PEARL

**From 0 to 45 degrees, closed-chain exercises are recommended, and from 45 to 90 degrees, open-chain exercises are recommended to minimize PF reaction forces during PF rehabilitation.**

The Q angle is defined in extension as the angle between the line of pull of the quadriceps (anterior superior iliac spine to center of patella) and patellar tendon (center of patella to center of tibial tubercle) (Fig. 35-2). Angles greater than 20 degrees are considered abnormal, reflecting a net lateral moment during quadriceps contraction. The lateral moment is normally counteracted by the VMO and static restraints. Measuring the tubercle-sulcus Q angle (the relative position of the tibial tubercle to the inferior pole of the patella at 90 degrees) is preferred by many, as it accounts for the effects of malalignment. Angles greater than 8 to 10 degrees are consistent with a lateralized distal patella vector primarily due to malalignment.

### PITFALL

**By itself, the Q angle is insufficient to determine the source or treatment of PF pain.**



**Figure 35-2** Quadriceps angle formed by intersection of the quadriceps tendon vector and the patellar tendon vector. More than 20 degrees is considered abnormal. Reprinted with permission from Insall JN. *Surgery of the Knee*. New York, NY: Churchill Livingstone, 1984: 195.

### Anatomy Embryology

The patella is the largest of the sesamoid bones and forms within the quadriceps muscle as early as 7.5 weeks gestation. The trochlear groove forms before fetal knee motion and is thought to be primarily genetically determined.

### Articular surface

The patella has the thickest articular surface in the body. It is divided into medial and lateral facets by a central ridge or crest. The medial facet has a separate, odd (vertically oriented) facet with limited trochlear contact during flexion. The larger, lateral facet is concave in both the longitudinal and transverse planes.

### Synovium

The plica synovialis mediopatellaris is an embryologic remnant of the medial-based synovial fold extending from the suprapatellar pouch around the patella to the fat pad distally.

### Soft tissue stabilizers

These circumferentially converge on the patella, including:

1. cephalad: quadriceps tendon

2. distal: patellar tendon
3. medial: VMO, retinaculum and PF ligament
4. lateral: vastus lateralis tendon, retinaculum, and iliotibial band (ITB)

The medial PF ligament is the major restraint to lateral displacement (53%). Capsular thickenings, called patellomeniscal ligaments (Kaplan's ligaments), are thought to be the cause of referred joint line pain in PF disorders.

### *Vascular and Arterial Supply*

Circumferential anastomoses of the four genicular, the supreme genicular, and the medial and anterior tibial recurrent arteries comprise the majority of the arterial supply. Venous drainage is by the popliteal and internal saphenous veins.

### *Innervation*

Nociceptive pain fibers within the lateral retinaculum are believed to be a cause of anterior and PF knee pain.

## **Examination**

### *History*

#### *Mechanism*

Ask the patient about specific patellar trauma, subluxation, or dislocation.

#### *Pain*

Patients with PF disorders often have poorly localized dull ache exacerbated by prolonged sitting ("movie sign") or stair climbing. This is often bilateral and of insidious onset. Locations most commonly include anteromedial, retropatellar, and posterior. Pain in long-standing PF disease may be from soft tissue contractures, lateral retinacular pain fibers, and arthrosis.

#### *Giving Way*

Patellofemoral "giving way" may represent patellar instability or occur secondary to painful quadriceps inhibition unlike that which occurs secondary to ligamentous instability where the knee "comes apart."

#### *Crepitus*

Crepitus is often bothersome to the patient, not commonly associated with pain, and not to be overtreated. Sources include malalignment, synovial impingement, quadriceps tendon, and chondrosis.

#### *Locking*

A patient may have a catching sensation that occurs during extension under load (stair-climbing or chair-rising), unlike meniscal pathology where the knee "locks up."

#### *Swelling*

Swelling is less common in PF disorders. It suggests intra-articular pathology. Peripatellar soft tissue swelling can also occur.

## **PEARL**

**Bilateral complaints of pain of insidious onset exacerbated by prolonged sitting with the knee in a flexed position or while negotiating stairs is relatively common in PF disease.**

### *Physical Examination*

In addition to tests specific for PF disorders (below), the exam should include tests necessary to establish other pathologic conditions that may exist.

#### *Observation*

Evaluate for foot pronation, external tibial torsion, genu valgum, femoral anteversion (hip internal rotation) and valgus, gynecoid pelvis, flexion contractures, patellar subluxation and Q angle measured in extension and flexion.

#### *Palpation*

##### **Effusion**

Use distally directed pressure on the suprapatellar area with the palm of one hand while balloting the patella medially with the other hand.

##### **Tenderness**

Palpate for tenderness in all anterior knee structures including entire extensor mechanism, medial/lateral patellar facets, retinaculum, epicondyles, ITB, pes anserinus, joint line, and fat pad.

##### **Flexibility and Strength**

Evaluate quadriceps (prone knee flexion), hamstrings (supine popliteal angles), and ITB for abnormal flexibility and strength.

##### **Creptus**

Apply posteriorly directed patellar pressure during active and passive range of motion (ROM). Note the presence of pain and where in the flexion arc it occurs.

##### **Percussion**

Evaluate for neuromas at prior surgical sites.

#### *Special Tests*

##### **Lateral Pull Sign**

Test for VMO insufficiency leading to disproportionate superolateral pull of the patella with quadriceps contraction with the knee in extension.

##### **J Sign**

Persistent lateral patellar movement with flexion (J sign) rather than inferomedial may occur with PF malalignment.

##### **Extensor Lag**

Passive range of motion (PROM) greater than active range of motion (AROM) is consistent with quadriceps insufficiency.

### Patellofemoral crepitus

This is often indicative of chondromalacia. It is graded: none ( $0^+$ ), mild ( $1^+$ ), moderate ( $2^+$ ), and severe ( $3^+$ ). Patellofemoral joint compression with the palm of the hand may recreate symptoms. Crepitus alone does not confirm PF dysfunction.

### Passive Patellar Tilt

This test is performed with the knee in full extension to assess side-to-side differences in the ability to elevate the lateral edge of the patella (Fig. 35-3). Zero degrees = normal (parallel),  $< 0$  degrees = tight lateral retinaculum (negative tilt).

### Patellar Glide

Perform this test with the knee in 30-degree flexion to engage patella into trochlear groove (Fig. 35-3b). Normal: 2-quadrant displacement medial or lateral without pain or apprehension (subjective feeling that the patella will dislocate). Abnormal: apprehension with  $> 2$ -quadrant lateral displacement with the ability to nearly or completely dislocate the patella ( $> 4$  quadrants); reduced medial displacement with excessive lateral compression syndrome (ELCS) or a tight lateral retinaculum.

## Aids to Diagnosis

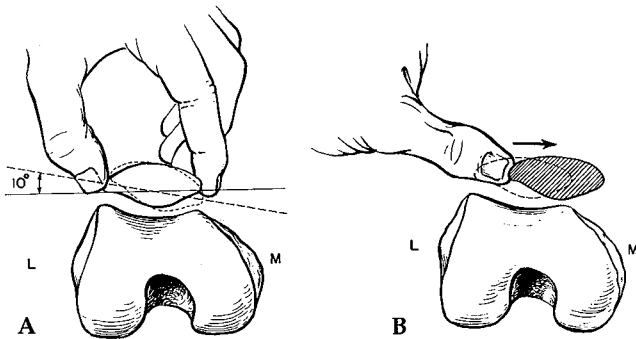
### Radiographic Evaluation

#### Standard Anteroposterior View

Use this extension weight-bearing radiograph to evaluate for soft tissue abnormalities, fractures, joint space narrowing, osteochondritis dissecans (OCD), loose bodies (from medial facet/lateral femoral condyle), and overall alignment.

#### Posteroanterior View (45 degrees) (Rosenberg, 1988)

A 45-degree posteroanterior (PA) flexion weight-bearing radiograph (x-ray parallel to tibial plateau, centered at joint line) is sensitive for early joint space narrowing, OCD, and evaluation of notch.



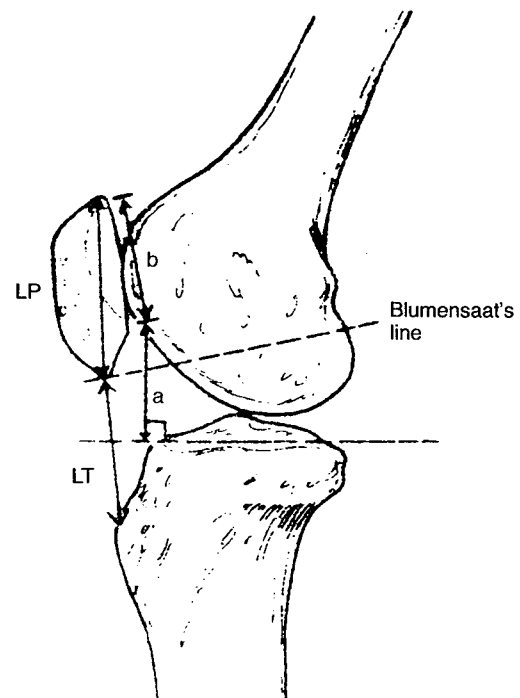
**Figure 35-3** Special tests for patellar mobility. (A) Patellar tilt is based on a neutral position parallel to the horizontal plane (solid line). A negative tilt is associated with tight lateral restraints. (B) Patellar glide is measured based on the number of quadrants the patella can be passively translated medially (M) or laterally (L). Reproduced with permission from Fu FH, Maday MG. Arthroscopic lateral release and the lateral patellar compression syndrome. *Orthop Clin North Am.* 1992, 23:603.

#### Lateral View

Use a lateral decubitus radiograph with knee flexed 30 to 45 degrees, placing the patellar tendon under tension. Evaluate subchondral sclerosis and patellar alta/baja (limitations) based on the Blumensaat line (knee must be flexed 30 degrees), the Insall-Salvati index, and the Blackburne and Peel index often associated with PF dysfunction (Fig. 35-4). Look for fragmentation of the inferior pole of the patella (Sinding-Larssen-Johanssen) or tibial tubercle (Osgood-Schlatter).

#### Patellar Views (Axial Views)

Wiberg (1941) described different facet configurations according to the ratio of the size of the medial and lateral facets (I: 24%, II: 57%, III: 19%) (Fig. 35-5). Type III is associated with a wide, lateral PF ligament, a predominant lateral facet (3:1), and lateral instability. Lateral displacement of the patella may be normal from 0 to 20 degrees of flexion. Excessive patellar



**Figure 35-4** Composite illustration of three popular methods of evaluating patellar alta/baja. 1. Blumensaat's Line: With the knee flexed 30 degrees, the lower pole of the patella should lie on a line extended from the intercondylar notch. 2. Insall-Salvati index: Patella tendon length (LT) to patella length (LP) should be 1.0 cm. An index greater than 1.2 is patella alta, an index less than 0.8 is patella baja. 3. Blackburne and Peel index: The ratio of the distance from the tibial plateau to the inferior articular surface of the patella (a) to the length of the patella articular surface (b) should be 0.8. An index greater than 1.0 is considered patella alta. Reproduced with permission from Harner CD, Miller MD, Irrgang JJ. Management of the stiff knee after trauma and ligament reconstruction. In: Siliski JM, ed. *Traumatic Disorders of the Knee*. New York, NY: Springer-Verlag; 1994:364.




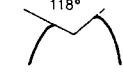

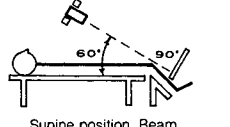
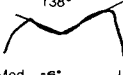

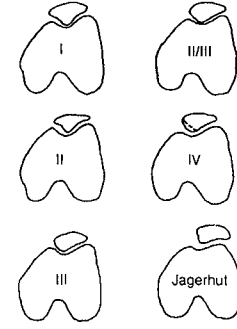
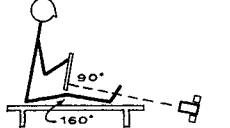



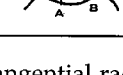
TANGENTIAL VIEW	KNEE FLEXION	TECHNIQUE AND POSITION	MEASUREMENTS	MISCELLANEOUS
Hughston	55 degrees	 <p>Prone position. Beam directed cephalad and inferior, 45 degrees from vertical.</p>	1) Sulcus angle: $118^\circ$  2) Patella index: $\frac{AB}{XB - XA}$ NL: Male 15 Female 17 	<ul style="list-style-type: none"> <li>Patellar dislocation</li> <li>Osteochondral fracture</li> <li>Soft tissue calcification (old dislocated patella or fracture)</li> <li>Patellar subluxation</li> <li>Patellar tilt</li> <li>Increased medial joint space</li> <li>Apex of patella lateral to apex of femoral sulcus</li> <li>Lateral patella edge lateral to femoral condyle</li> <li>Hypoplastic lateral femoral condyle (usually proximal)</li> </ul>
Merchant	45 degrees	 <p>Supine position. Beam directed caudal and inferior, 30 degrees from vertical.</p>	1) Sulcus angle: $138^\circ$  2) Congruence angle: 	<ul style="list-style-type: none"> <li>Patellofemoral osteophytes</li> <li>Subchondral trabeculae orientation (increase or decrease)</li> <li>Patellar configuration (Wiberg-Baugart)</li> </ul> 
Laurin	20 degrees	 <p>Sitting position. Beam directed cephalad and superior, 160 degrees from vertical.</p>	1) Lateral patellofemoral angle: NL:  ABNL:  ABNL:  2) Patellofemoral index: Ratio A/B Normal = 1.6 or less 	

Figure 35-5 Patellofemoral (PF) measurements on plain tangential radiographs. Reproduced with permission from Carson WG et al. Patellofemoral disorders; physical and radiographic evaluation. Part I: physical examination. *Clin Orthop.* 1984;185:126.

tilt is best demonstrated at 20 to 30 degrees using Laurin's view. Subluxation decreases from 0 to 30 degrees of flexion and is best measured using the Mercer-Merchant view at 45 degrees flexion. Lateral facet arthrosis is seen as subchondral sclerosis, cyst formation, perpendicular trabeculae, facet collapse, lateral margin patellar osteophytes, or fractures and calcification within the lateral retinaculum. Medial facet osteoporosis may be present from relative unloading.

**Sunrise View**

In this view, the knee is flexed 60 to 90 degrees and the beam is tangential to the PF joint. One can see more of the femoral condyles than on other to views described below. The sunrise view is good for patellar fractures, dislocations, loose bodies and articular irregularities but not for malalignment measures.

**Mercer-Merchant View**

The knee is flexed 45 degrees, and the X-ray is angled caudad 30 degrees in this view (Fig. 35-6). The sulcus angle (Normal: 140 degrees  $\pm$  5 degrees) and the congruence angle (Normal: -6 degrees  $\pm$  11 degrees) are formed between lines bisecting the sulcus and median crest, reflecting patellar centralization and/or subluxation. Normally, the median crest bisector (solid line) is medial to the sulcus bisector (broken line) and is considered negative by convention. A congruence angle greater than 16 degrees is diagnostic of lateral subluxation.

**Laurin View**

This is a 20-degree tangential view. The lateral PF tilt angle is the intersection of the line connecting the peaks of the femoral




Figure 35-6 A typical Merchant's view suggesting lateral patellar subluxation. Only the anterior one-third of the condyles are imaged compared to a sunrise view demonstrating most of the femur. Note lateral subluxation and tilt of the left patella.

condyles with a line along the lateral facet reflecting patellar tilt. The medial opening reflects tilt.

### PEARL

**Subluxation is best measured using Mercer-Merchant view (congruence angle), whereas tilt is better evaluated using Laurin's view (PF tilt angle).**

### PITFALL

**A tight, lateral retinaculum causing medial rotation of the central ridge may suggest medial subluxation, which is actually only tilt without subluxation. Medial subluxation without previous surgery is extremely rare.**

#### *Computed Tomographic Scan*

Detection of PF malalignment is more sensitive earlier in flexion before it engages in the trochlea. Midpatellar transverse computed tomography (CT) scans performed in 15, 30, and 45 degrees of flexion prevent image overlap or distortion seen in plain radiographs. Subluxation (congruence angle with central ridge of patella well medial to bisected trochlea) and tilt (lateral PF tilt angle > 12 degrees) is more accurately referenced from the posterior condyles of the femur.

#### *Magnetic Resonance Imaging*

Kinematic axial magnetic resonance imaging (MRI) is investigational. Articular or osseous lesions may be identified as well as other intra-articular pathology.

#### *Bone Scan (Technetium Scintigraphy)*

A bone scan differentiates articular from soft tissue sources of pain. In reflex sympathetic dystrophy (RSD), typically uptake is diffuse. In PF disorders, the patella is "hotter" than the distal femoral diaphysis.

### PITFALL

**Imaging studies alone cannot be used definitively to make diagnosis of painful dysfunction of the PF joint.**

## **Specific Conditions, Treatment, and Outcome**

### *Nonpatellofemoral Causes of Anterior Knee Pain*

Common to the many etiologies of anterior and PF pain are quadriceps atrophy, weakness, and chronic effusions. Radiographic evaluation is used to rule out malalignment and unsuspected bony pathology. Evaluation and treatment is problem specific as described in this section.

#### *Plica*

A diagnosis of exclusion, especially in the presence of notching ("kissing lesion") of the medial femoral condyle related to contact with the plica at 30 to 40 degrees of flexion. Patients present with a history of overuse, trauma, or prior surgery. Palpation reveals a tender band along the medial peripatellar retinaculum. Injection or arthroscopic resection is usually curative.

#### *Tendonitis*

Patellar tendonitis ("jumper's knee") presents with distinct tenderness at the origin of the patellar tendon. Relaxation and extension facilitates deep palpation. Treatment includes correction of training errors, rest, progressive strengthening and stretching, multimodality physical therapy, injection and patellar tendon strapping. Surgical exploration and excision is rarely required. Quadriceps tendonitis is less common and similarly treated.

#### *Bursitis*

Prepatellar bursitis ("housemaid's knee") presents as a spectrum ranging from acute, swollen, boggy, and tender inflammation to chronic, thickened skin anterior to the patella. Acutely, infection must be ruled out. Surgical excision is rarely required. Inflammation of the pes anserinus is diagnosed by palpation of the sartorius, gracilis, and semitendinosus common tendon insertion along the proximal anteromedial tibial metaphysis. Treatment is similar to tendonitis.

#### *Fat Pad Syndrome*

A direct blow or hyperextension injury may traumatize the anterior or infrapatellar fat pad. Symptoms resolve with symptomatic treatment. Hoffa's disease, chronic infrapatellar fat pad fibrosis and calcification, may result from recurrent trauma. Surgical excision or release is often necessary.

#### *Chronic Effusion*

Generalized synovitis secondary to intra-articular pathology or inflammatory disease may cause quadriceps inhibition resulting in increased PF joint stress. Treatment is directed toward the specific condition.

#### *Iliotibial Band Friction Syndrome*

Overuse may lead to painful inflammation in the region of the lateral femoral epicondyle as the ITB flexes and extends the knee. Risk factors include genu varum, internal tibial torsion, and excessive pronation. Treatment is similar to tendonitis, emphasizes stretching, and occasionally requires partial ITB excision.

#### *Tumorous Conditions*

Quadriceps hemangiomas, synovial chondromatosis, osteoid osteoma, and osteochondroma are some of the tumorous conditions that may cause effusion and anterior knee pain. Appropriate suspicion, radiographic evaluation, and lesion-directed excision is required.

#### *Referred Pain*

Examination of the back, hips and ankle for age-specific pathology may reveal a remote source of anterior knee pain.

### *Patellar Osteochondritis Dissecans*

This condition rarely may occur along the lateral facet. It is diagnosed best by lateral and axial radiographs. Treatment is determined by the stage of the lesion, including immobilization or drilling (stage I), drilling and fixation (stages II and III), and abrasion chondroplasty with excision (stage IV).

### *Saphenous Neuralgia and Varices*

The inferomedial arthroscopic portal or trauma may damage the infrapatellar branch of the saphenous nerve or peripatellar tissues. Patients complain of numbness or burning along the anterior knee that remains symptomatic at rest. Discrete tenderness is relieved by injection of 1% lidocaine (Xylocaine). Neuroma excision is usually curative. Anterior saphenous varices present with activity-related swelling about the medial side of the knee that decreases with elevation. Vascular consultation and ligation may be curative.

### *Cruciate Ligament Insufficiency*

Cruciate insufficiency, treated conservatively or with reconstruction, may present with anterior knee pain. Some reports on the use of hamstring rather than patellar tendons for anterior cruciate ligament (ACL) reconstruction have demonstrated decreased rates of PF pain.

### *Adolescent Anterior Knee Pain*

This is a broad category and includes PF malalignment, excessive lateral compression syndrome, patella alta/baja, muscle imbalance, Sinding-Larssen-Johanssen disease, Osgood-Schlatter's disease, and hypermobility of the patella secondary to excessive ligamentous laxity. Most of these conditions are treated with conservative modalities (i.e., physical therapy and relative rest) and rarely require surgery.

### *Reflex sympathetic dystrophy*

Patients with reflex sympathetic dystrophy have histories of trauma leading to severe anterior knee pain even at rest, atrophy, skin changes (shiny, red, warm, alopecia) and symptoms out of proportion to the inciting event. Radiographs may show diffuse osteopenia. Bone scans show a "hot" PF joint. Treatment includes desensitization, physical therapy, and sympathetic blockade.

## *Patellofemoral Disorders*

The term patellar instability is specific to patients with a history of lateral subluxation or dislocation, but it may also include patients with ELCS. Articular damage is a common sequelae of long-standing tilt and recurrent instability. A history of trauma, effusion, and crepitus with reproduction of symptoms with PF compression is common.

Operative treatment assumes that at least 3 months of nonoperative treatment have failed. Treatment of PF instability includes lateral release (LR), proximal realignment, and medial tubercle transfer. Treatment of articular degeneration includes chondroplasty, tubercle elevation, patellectomy, and arthroplasty. In general, tubercle elevation reduces sagittal plane forces; and LR, proximal realignment, and medialization of the tubercle reduces coronally directed forces. Combinations of the above procedures should be utilized when appropriate.

### *Excessive Lateral Compression Syndrome (isolated patellar tilt)*

#### **Definition**

The definition of ELCS is chronic lateral tilt and compression of the patella from lateral retinacular tightness without instability, hypermobility, or abnormal Q angle.

#### **History**

The patient will have a history of activity-related bilateral anterior knee pain with stairs or sitting.

#### **Physical Findings**

On examination one finds negative patellar tilt, decreased medial patellar glide, loss of flexibility, facet and retinacular tenderness, positive lateral pull and J signs.

#### **Radiologic Findings**

Radiologic workup shows abnormal lateral PF tilt angle, normal or nearly normal congruence angle, and patellar arthrosis.

#### **Treatment**

Treatment comprises arthroscopy, chondral debridement, and LR. High-grade arthrosis may require additional antero-medialization of the tubercle.

### *Patellar Instability*

#### **Definition**

Patellar instability is a spectrum ranging from patellar subluxation to frank dislocation.

#### **History**

There will be a history of patellar slipping with cutting maneuvers and a possible history of trauma.

#### **Physical Findings**

Apprehension, increased lateral patellar glide, and negative patellar tilt with lateral retinacular tightness are often present.

#### **Radiologic Findings**

Abnormal congruence angle and abnormal lateral PF angle with tilt are found.

#### **Treatment**

Treatment comprises LR only with normal alignment; medial tubercle transfer with evidence of malalignment and low-grade arthrosis. High-grade arthrosis requires anteromedialization of the tubercle.

### *Patellar Arthrosis*

#### **Definition**

Varying degrees of arthritis due to trauma and/or malalignment define patellar arthrosis.

#### **History**

There will be a history of pain primarily with stairs and extension and, possibly, a remote history of trauma.

**Physical Findings**

There is no significant malalignment and retropatellar crepitus exacerbated by palmer pressure, or facet tenderness and effusion are typically present.

**Radiologic Findings**

Findings include patellar arthrosis and positive bone scan.

**Treatment**

Treatment comprises arthroscopic debridement, anteromedialization of the tibial tubercle, patellectomy, or arthroplasty.

*Nonoperative Treatment*

Most patients with PF malalignment can be treated with non-operative means. Individualized and pain-free rehabilitation should be attempted for at least 3 months before surgical intervention is considered. Variations of this protocol are used for postoperative rehabilitation with relative protection of surgical reconstructions.

*Phase I*

Reduce inflammation and effusion, improve VMO control of patellar tracking, improve flexibility, and institute soft tissue stretching and McConnell taping techniques to correct soft tissue imbalances. Patellar sleeves or dynamic braces are controversial, but sometimes helpful.

*Phase II*

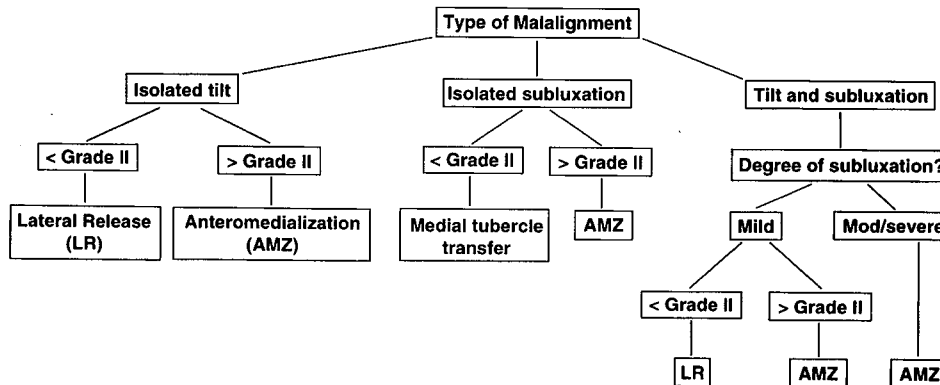
Isotonic eccentric and concentric strengthening with emphasis on muscle endurance and adduction facilitating VMO contraction is introduced. Institute closed-chain exercises in extension and open-chain exercises in flexion. Avoid isokinetics.

*Phase III*

Introduce proprioceptive and sport-specific functional training. Use plyometrics, aquatics, running, and agility drills.

*Operative Treatment*

Fig. 35-7 represents a three-arm algorithm (adapted from Post, 1994) for surgical decision making should conservative measures fail to resolve the patient's symptoms. Procedures are chosen based upon the degree of articular arthrosis and the presence of PF malalignment.



**Figure 35-7** Algorithm for surgical treatment of PF malalignment. Reproduced with permission from Post WR. Surgical decision making in patellofemoral pain and instability. *Oper Tech Sports Med.* 1994;2:280.

*Diagnostic Arthroscopy*

**Goals**

Define the specific pathology to facilitate treatment.

**Indications**

Adjunct to additional procedures.

**Techniques**

View surgical site superolaterally or superomedially with a 30-degree scope. The patella should articulate laterally at 10 to 20 degrees, centralize and articulate medially at 30 to 40 degrees.

**Results and Complications**

These are dependent on the specific pathology.

*Arthroscopic Chondral Debridement*

**Goals**

The goal of this procedure is the removal of unstable chondral flaps; abrasion chondroplasty to stimulate fibrocartilage formation is of questionable benefit.

**Indications**

Use arthroscopic chondral debridement with traumatic chondral flaps or as an adjunct to a realignment procedure.

**Techniques**

Basket forceps and a rotary shaver are used to excise fronds and fibrillations. Beveling of normal cartilage should be avoided.

**Results**

This procedure does not prevent progression of underlying disease. Results are best with isolated patellar chondromalacia or traumatic lesions.

**Complications**

Damage to normal cartilage may occur.

*Lateral Release*

**Goals**

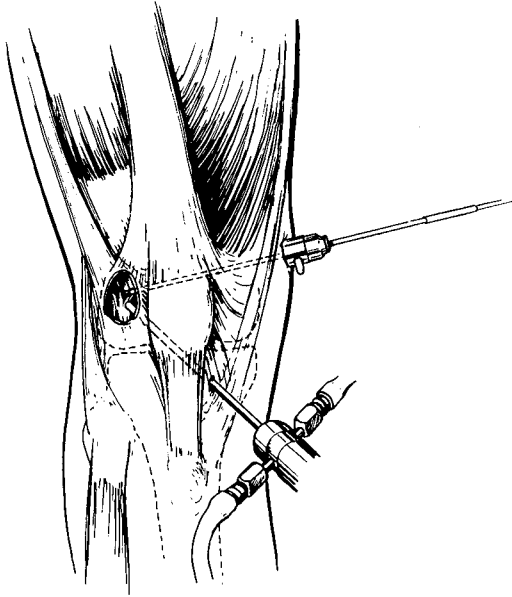
Relieving posterolateral tether and tilt, decreasing lateral facet stress, improving congruence in combination with other realignment procedures, and improving dynamic VMO function are the goals of LR. By itself, LR will not affect subluxation.

### Indications

Indications comprise pain greater than instability, ELCS, minimal subluxation, low-grade arthrosis (grade I or II), minimal hypermobility, and nearly normal Q angle.

### Techniques

Arthroscopic, subcutaneous, and mini-open techniques are employed. Use a retinacular release 1 to 2 cm lateral to the patella from the joint line to the distal most portion of the vastus lateralis (Fig. 35-8). After LR, the patella should be able to be passively tilted 80 degrees.



**Figure 35-8** Arthroscopic technique for the lateral release (LR). Inferomedial portal for viewing and inflow and superomedial portal 3 to 6 cm proximal to superior pole of patella for intra-articular release using electrocautery. Reproduced with permission from Fu FH, Maday MG. Arthroscopic lateral release and the lateral patellar compression syndrome. *Orthop Clin North Am.* 1992;23:608.

### Results

Success rates of 85 to 90% can be achieved in properly chosen patients. Long-term results deteriorate with higher grades of chondrosis (stage III or IV), patellar instability, and hypermobility.

### Complications

Complications can include hemarthrosis, infection, RSD, arthrofibrosis, neuroma, medial subluxation of the patella, and worsened pain without evidence of tilt. Greater contact on the distal medial facet in the presence of articular lesions may cause crepitus after LR.

### PEARL

After a lateral release (LR), obtain hemostasis at the level of the superior pole (lateral superior geniculate artery) and lateral joint line (lateral inferior geniculate artery) to prevent postoperative hemarthrosis.

### Proximal Realignment

#### Goals

Increased static posteromedial restraint to limit subluxation. The Q angle is not altered, but patellofemoral incongruence is corrected.

#### Indications

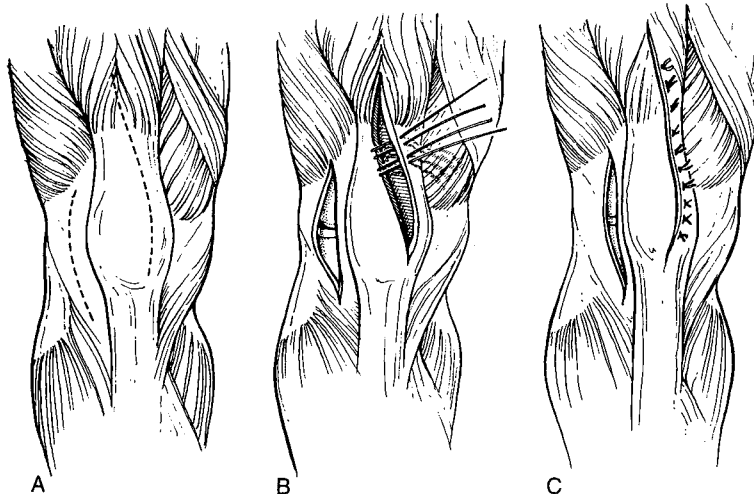
A need for greater static restraint in the presence of lateral tilt when LR alone is felt to be insufficient.

#### Techniques

A proximal medial VMO imbrication with lateral release is used (Fig. 35-9).

#### Results

Combined with lateral release, proximal realignment offers no clear benefit to LR alone.



**Figure 35-9** Proximal realignment. (A) After exposure of the quadriceps, two incisions are made. The first enters the knee joint through a medial parapatellar arthrotomy at the margin of the vastus medialis and the second is a LR. (B) Realignment is accomplished by advancing the medial flap laterally and distally in line with the fibers of the vastus medialis obliquus. (C) After suturing, the incision lies in a straight line across the front of the patella, and the ER should open widely. Reproduced with permission from Miller MD, Cooper DE, and Warner JP. *Review of Sports Medicine and Arthroscopy.* Philadelphia, PA: WB Saunders; 1995:58.

### **Complications**

Possible complications include quadriceps dysfunction, phlebitis, hematoma, arthrofibrosis, recurrent instability, and potentially increased medial PF contact stress, if performed alone.

#### *Distal Realignment Procedures*

### **Medial tibial tubercle transfer**

#### *Goals:*

Decreasing the lateral quadriceps vector and the tendency to subluxate.

#### *Indications:*

Recurrent instability with minimal pain, low grade arthrosis and increased Q angle.

#### *Techniques:*

Roux-Elmslie-Trillat procedure: LR, proximal realignment, and straight medial displacement of the tibial tubercle.

#### *Results:*

In properly indicated patients, 80% good to excellent results can be expected.

### **Tibial tubercle anteromedialization**

#### *Goals:*

Decreasing sagittal and coronal plane PF contact forces. Moving the tubercle anteriorly unloads, distal and lateral facets; moving the tubercle medially improves Q angle and instability.

#### *Indications:*

Recurrent instability, patellar tilt with moderate to severe pain, and high-grade arthrosis (> II), especially with distal medial or central lateral facet arthrosis.

#### *Techniques:*

Oblique anteromedial to posterolateral osteotomy resulting in anterior (> 10 mm) and medial translation (> 8 mm) (Fig. 35-10). Combine osteotomy with LR.

#### *Results:*

Even with high grade (III or IV) arthrosis, results are 70 to 90% excellent or good.

### **Tibial tubercle elevation**

#### *Goals:*

Decreasing the distal sagittal plane PF contact force with load shifting away from distal articular lesions to proximal articular surface is the goal of tibial tubercle elevation.

#### *Indications:*

Pain with high-grade arthrosis without malalignment or instability in patients who are not candidates for athroplasty or patellectomy.

#### *Techniques:*

The tibial tubercle is elevated 2 cm on the distal-based shingle and a tricortical, iliac crest bone graft is used. Alternatively, an oblique osteotomy will reduce the required size of the iliac crest bone graft.

#### *Results:*

PF joint reaction force is reduced 50%. Results are best in post-traumatic arthrosis (> 90% satisfactory).

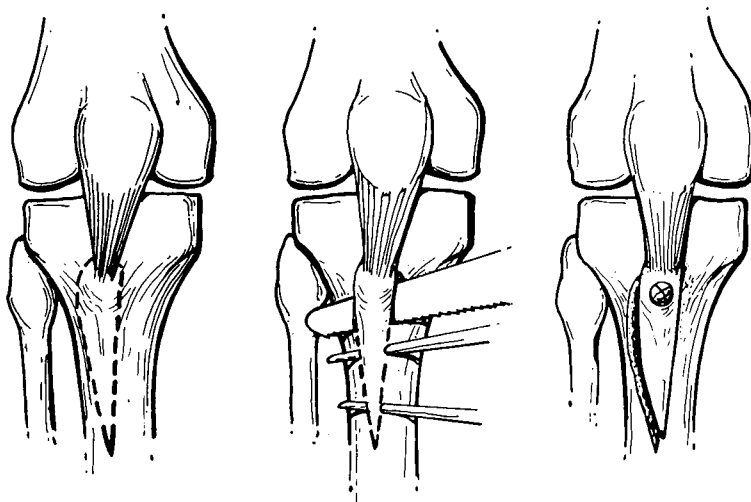
#### *Distal realignment complications:*

Inadvertent posterior displacement increasing PF contact force and arthrosis may occur following a Hauser procedure. Anteromedialization may cause proximal medial patellar pain, if lesions exist there. Inadequate correction, nonunion, infection, arthrofibrosis, recurrent instability, skin necrosis (if elevated > 2 cm) and growth arrest in skeletally immature patients may occur.

### **Patellectomy**

#### *Goals:*

Relief of pain with relative improvement in overall function.



**Figure 35-10** Anteromedial transfer as described by Fulkerson. Reproduced with permission from Walsh WM. Patellofemoral joint. In: DeLee JC, Drez D Jr, eds. *Orthopaedic Sports Medicine: Principles and Practice*. Philadelphia, PA: WB Saunders; 1994;1233.

*Indications:*

Severe pain from extensive articular lesions limiting quadriceps function that are not amenable to realignment or anteriorization.

*Techniques:*

Longitudinal side-to-side repair, "purse-string" imbrication, and transverse proximal-to-distal repair are techniques employed. They can be combined with LR and proximal realignment.

*Results:*

At follow up of more than 5 years, results are 33 to 60% excellent.

*Complications:*

A strength deficit of 30 to 50% with symptoms of giving way may occur.

**Patellofemoral Arthroplasty**

*Goals:*

Relief of pain with relative improvement in overall function.

*Indications:*

Isolated PF arthritis in elderly or low-demand individuals.

*Techniques:*

Patellar resurfacing or total PF replacement is employed.

*Results:*

The best results are achieved when malalignment is addressed: up to 85% good or excellent at 2 to 12-year followup.

*Complications:*

Loosening, wear, and infection can occur.

## **Summary**

Anterior knee pain may have a variety of causes, only some of which are due to PF disorders. Diagnosis and treatment is difficult and is predicated on a systematic history and physical examination. Radiographic evaluation may offer additional information to diagnose and treat PF disorders. Chondromalacia should not be used as a substitute term to describe anterior knee or PF pain. Performing a LR as a panacea to treating all conditions presenting with anterior knee pain is to be condemned. Rigorous attempts at rehabilitation are usually successful. In the event that surgical intervention is required, malalignment (i.e., tilt, instability) and arthrosis must be completely evaluated and addressed by the chosen procedure.