

Meniscal Allograft Transplantation: Preoperative Assessment, Surgical Considerations, and Clinical Outcomes

Randy Mascarenhas, MD¹ Adam B. Yanke, MD¹ Rachel M. Frank, MD¹ Davietta C. Butty, BS¹
 Brian J. Cole, MD, MBA²

¹Department of Orthopedic Surgery, Rush University Medical Center, Chicago, Illinois

²Division of Sports Medicine, Department of Orthopedics, Rush University Medical Center, Chicago, Illinois

Address for correspondence Brian J. Cole, MD, MBA, Division of Sports Medicine, Department of Orthopedics, Rush University Medical Center, Midwest Orthopaedics, 1611 West Harrison Street, Suite 300, Chicago, IL 60612 (e-mail: bcole@rushortho.com).

J Knee Surg

Abstract

The purpose of this review is to characterize the preoperative assessment of meniscal allograft transplantation (MAT) candidates, to detail MAT surgical techniques, and to evaluate current clinical outcome data on MAT. The MAT candidate is typically less than 50 years old and has a history of knee injury, previous meniscus surgery, and persistent pain. Physical exam generally reveals knee pain with joint line tenderness with normal radiographs and magnetic resonance imaging demonstrating the postmeniscectomized state. There are several common surgical techniques used for transplantation, with fixation achieved through sutures, bony fixation, or a combination of the two. Concomitant procedures such as anterior cruciate ligament reconstruction, osteotomy, and other cartilage procedures are commonly performed. The available short- and long-term studies of clinical outcomes of MAT are variable and difficult to effectively compare due to heterogeneity of the study population and available treatment techniques. In addition, there are no published randomized controlled trials. However, recent reviews and cohort studies of clinical outcomes following MAT have shown that whether performed in isolation or performed with concomitant articular cartilage, realignment, or soft tissue reconstruction procedures MAT outcomes have been acceptable with the majority of studies reporting improved clinical outcomes regardless of the scoring system employed. MAT has proven to be a safe and effective technique in reducing knee pain and improving function in the symptomatic meniscal deficient knee. Evaluation of long-term clinical outcomes is necessary as is evaluation of meniscal replacement alternatives.

Keywords

- ▶ meniscal transplant
- ▶ clinical outcomes
- ▶ technique

As the biomechanical and clinical consequences of subtotal meniscectomy have become evident,¹⁻⁴ treatment of meniscus tears has evolved to exhausting attempts at repairing the injured meniscus or preserving as much meniscal tissue as possible when performing a partial meniscectomy. Pain, recurrent swelling, and the eventual development of

osteoarthritis are not uncommon sequelae in the meniscectomized knee. Accordingly, meniscal transplantation has been proven as an effective procedure in reducing pain and increasing function in patients under the age of 50 years with a symptomatic, meniscal-deficient knee. Studies have shown good outcomes in short- and

received
 March 14, 2014
 accepted
 April 24, 2014

Copyright © by Thieme Medical Publishers, Inc., 333 Seventh Avenue, New York, NY 10001, USA.
 Tel: +1(212) 584-4662.

DOI <http://dx.doi.org/10.1055/s-0034-1382080>.
 ISSN 1538-8506.

medium-term studies, but longer term studies are required to examine the long-term effectiveness of the procedure. This review serves to summarize the perioperative and operative factors involved with meniscus transplantation and the associated evidence regarding clinical outcomes.

Anatomy and Biomechanics

The menisci are semilunar fibrocartilaginous structures that function in shock absorption,⁵ joint lubrication,⁶ nutrition,⁷ load transmission,⁸ and knee stability.⁹ Circumferential collagen fibers resist hoop stresses, while radial fibers resist shear and hold circumferential fibers together.¹⁰ The menisci are almost three-quarters water by content, which optimizes their ability to aid in force transmission. The lateral meniscus bears 70% of the load sustained through the lateral compartment, while the medial meniscus bears 50% of the load in the medial compartment.⁸ Fifty percent of this load is transmitted with the knee in extension, with more than 90% transmitted when the knee is in flexion.⁸ Loss of meniscal tissue thus leads to increased forces borne through the articular cartilage of the knee and can predispose to the development of arthritic changes.¹¹ The role of meniscal allografts becomes apparent when evaluating the results of studies that have demonstrated fewer arthritic changes following meniscus transplantation in addition to lower contact pressures as compared with uncovered areas.¹²⁻¹⁴

Preoperative Assessment

History and Physical Exam

A thorough history is essential and should include the causative mechanism, associated injuries, and prior treatments. Patients frequently report a history of knee injury with subsequent surgical treatment (often multiple treatments) involving meniscus repair and/or meniscectomy. A period of symptomatic improvement usually follows the index procedure, but is generally followed by the development of ipsilateral joint line pain and activity-related swelling. Recent operative reports and arthroscopic images may be useful in identifying focal chondral defects or diffuse arthritic changes within the affected compartment.

Gait and standing alignment should be assessed on physical examination. Range of motion is usually preserved and patients may present with an effusion. Palpation generally reveals joint line tenderness along with occasional tenderness to palpation along the associated femoral condyle. Ligamentous stability of both the cruciate and collateral ligaments should be assessed as well.

Imaging

Standard radiographic assessment consists of anterior-posterior (AP) extension weightbearing views, posteroanterior 45-degree flexion weightbearing views, non-weightbearing 45-degree flexion lateral views, axial views of the patellofemoral joint, and three-foot standing long axis views to assess the mechanical axis. Hardware from previous surgeries

should be identified on preoperative radiographs if possible to determine the need for removal.

Magnetic resonance imaging (MRI) is also included in our standard preoperative imaging to assess for ligamentous insufficiency, focal chondral defects, the amount of affected meniscus remaining, and the degree of subchondral edema in the involved compartment (→ Fig. 1).

Indications and Contraindications

The ideal candidate for a meniscal transplantation procedure is the patient under 50 years of age who has previously undergone total or subtotal meniscectomy and has persistent pain specific to the meniscectomized compartment. Patients with coronal malalignment, cruciate ligament insufficiency, and/or focal chondral defects need to have these issues addressed concomitantly or via staged procedures to aid in a successful outcome following meniscal transplantation.

Contraindications to meniscal transplantation include diffuse arthritic changes and radiographic joint space narrowing. Radiographic femoral or tibial flattening, significant osteophyte formation, tibiofemoral subluxation, synovial disease, skeletal immaturity, inflammatory arthritis, previous or active joint infection, and marked obesity are also contraindications to transplantation.

Preoperative Planning

Sizing

Meniscal allografts are side, compartment, and size specific, and the success of meniscus transplantation is thus dependent on careful size matching of the allograft meniscus to the native knee. It has been shown that oversized allografts can lead to increased contact forces across the tibiofemoral articular cartilage, while undersizing the allograft can lead to increased forces across the transplanted meniscus.¹⁵

A consistent relationship generally exists between bony landmarks of the knee and the meniscal size, so transplant sizing is generally performed with tibial plateau length and width measurements as measured on standard AP and lateral

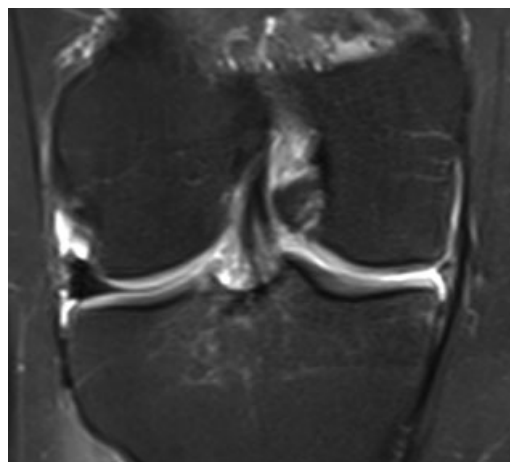


Fig. 1 Right knee magnetic resonance imaging of patient status post medial meniscectomy with maintained articular cartilage.

radiographs with magnification markers placed on the skin at the level of joint line. After accounting for radiographic magnification, meniscal width is measured on the AP radiograph as the distance between the ipsilateral tibial spine and the edge of the tibial plateau. Meniscal length is calculated by measuring the depth of the tibial plateau on lateral radiograph and multiplying by 0.8 for medial and 0.7 for lateral meniscus grafts. There exists some variation with these measurements and other sizing methods have thus been suggested.

The contralateral meniscus has been proven to measure within 3 mm of the affected meniscus in the symptomatic knee and may be more accurate than traditional radiographic sizing methods.¹⁶ In addition, height, weight, and gender have proven to be fast and cost-effective variables by which to predict meniscal dimensions more accurately than current radiographic parameters.^{17,18} In terms of age, donor grafts under the age of 45 years have been proven to have similar tissue properties regardless of specific age.¹⁹

Allograft Procurement and Processing

Ideally, meniscal allografts should be harvested and frozen within 24 hours of death. A majority of grafts are either fresh frozen or cryopreserved. Cryopreservation involves the use of dimethylsulfoxide to preserve cell viability, while the fresh-frozen method requires rapid cooling to -80°C , which is deleterious to cell viability but does not affect the biomechanical properties of the graft. Stringent donor selection is based on comprehensive screen for HIV, human T-lymphocytic virus, hepatitis B and C, and syphilis. Blood cultures for aerobic and anaerobic bacteria and lymph node sampling may also be performed. The risk of disease transmission is further lowered with graft processing including debridement, ultrasonic pulsatile washing, and the use of ethanol to denature proteins. An aseptic antibiotic soak is then used to further decrease the risk of disease transmission.

Surgical Procedure

There are several techniques for meniscus transplantation that are commonly used. Fixation of the transplanted meniscus may be achieved with sutures, bony fixation, or a combination of both. Bony fixation can be accomplished with separate bone plugs for the anterior and posterior horns or bone bridges (keyhole, trough, bridge-in-slot, and dovetail techniques). Medial meniscus transplants may be done via bone-bridge or separate plug techniques, but lateral transplants are almost always done with a bone-bridge technique due to the close proximity of the anterior and posterior horns.

Our preference is to perform the bridge-in-slot technique for both lateral and medial meniscus transplants due to bony fixation achieved, simplicity of performing concomitant procedures, and the ability to maintain native anterior and posterior horn attachments.

Equipment

The surgeon should have available and be well versed with the instrumentation to perform their preferred transplanta-

tion technique. The organization that supplied the meniscal allograft may provide a workstation to aid in preparing the transplanted meniscus to the correct size. Zone-specific cannulas and double-armed needles are required for the meniscocapsular repair.

Positioning

The procedure may be performed under either general or spinal anesthetic or a combination of the two. The patient is placed supine on a standard operating table with the foot of the bed down. The operative leg is held in a thigh holder to facilitate hyperflexion of the knee while the contralateral limb is positioned in a well-leg holder in flexion, abduction, and external rotation. Surgery is performed with a tourniquet inflated on the operative leg to aid with visualization and hemostasis. Standard preoperative antibiotics are administered before making any incisions, and an examination of the knee under anesthesia should be performed to assess stability.

Graft Preparation

The meniscal allograft can be prepared either during anesthesia induction time or following preparation of the tibial slot. The allograft tissue arrives as a hemiplateau with attached meniscus and should be thawed in normal saline before preparation. A single bone bridge is used to secure the graft to the tibial plateau and is undersized by 1 mm to ensure easy graft passage and reduce the risk of plug fracture with forceful insertion. The insertions of the anterior and posterior meniscal horns on the graft are identified, and any extraneous soft tissue is removed. The bone bridge is cut to a height of 1 cm and a width of 7 mm with removal of any bone posterior to the posterior horn attachment (►Fig. 2). The distance of the posterior tibia to the posterior meniscal insertion can be estimated intraoperatively using the graduated guide, and the amount of bone on the posterior aspect of the allograft should match this. Extra bone anterior to the anterior horn attachment site is preserved to maintain graft integrity during insertion. The remaining anterior and posterior meniscal attachment sites should measure approximately 5 to 6 mm, but the anterior horn attachment can sometimes measure as much as 9 mm. If this is the case, the anterior aspect of the bone bridge should be cut to match

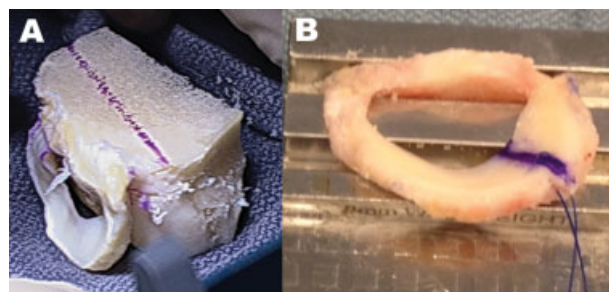


Fig. 2 (A) The allograft meniscus is first trimmed to a depth of 1 cm and then undersized by 1 mm (7 mm) for the 8 mm trough. (B) A passing suture is placed at the junction of the anterior two-thirds and the posterior one-third.

the size of the anterior meniscal attachment and then tapered to the desired 7 mm throughout the rest of the bone block. The recipient slot should also be widened to accommodate this larger bone plug. A number 0 PDS suture (Ethicon, Blue Ash, OH) is placed in a vertical mattress fashion as a traction suture at the junction of the posterior and middle third of the meniscus (►Fig. 2).

Intra-articular Preparation

Diagnostic arthroscopy is first performed in a standard fashion through inferolateral and inferomedial portals to evaluate for ligamentous insufficiency and focal chondral defects. The steps for meniscal transplantation are essentially the same whether a medial or lateral transplant is performed if performing a bone-bridge technique for both. The remnant of the native meniscus is debrided to a 1 to 2 mm peripheral rim until punctate bleeding occurs (►Fig. 3). Care should be taken to not penetrate the joint capsule. The anterior and posterior horn insertions can be maintained or at least noted as useful markers for slot preparation. A limited notchplasty on the ipsilateral femoral condyle affords improved visualization of the posterior horn and facilitates graft passage. While this is more useful in the medial compartment, it is typically not necessary for the bone-trough technique. The most medial anterior cruciate ligament (ACL) fibers at the tibial insertion should be released as little as possible to allow visualization of the medial tibial spine if medial meniscus transplantation is planned. Ideally, the spine on the meniscal transplant will align with the location of the patient's native tibial spine.

Arthrotomy

A miniarthrotomy is then made under spinal needle localization through the patellar tendon in line with its fibers to approach the anterior and posterior horn insertion sites of the involved meniscus. This facilitates introduction of the slot and placement of the allograft. An ipsilateral posteromedial or posterolateral incision is also required for the inside-out placement of the meniscocapsular repair sutures. These incisions should extend one-third above and two-thirds below the ipsilateral joint line and allow for safe placement of the

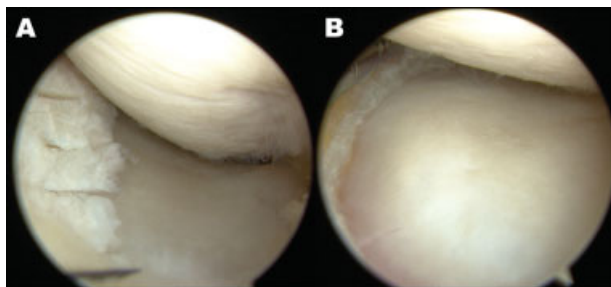


Fig. 3 Arthroscopic images of a left medial meniscus. (A) If a portion of the nonfunctional meniscus remains, removal can be aided by the use of a 11-blade scalpel to create access channels for the shaver. (B) The ensuing debridement should be performed carefully to leave the capsule intact and preserve approximately 1 mm of the peripheral aspect of the meniscus to improve repair integrity.

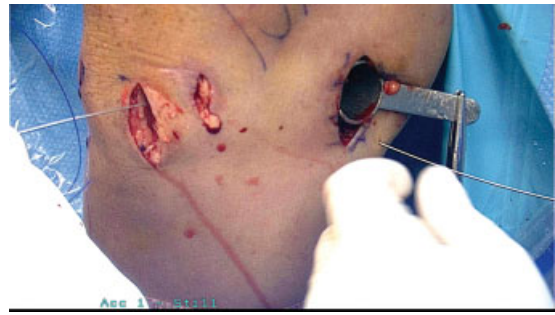


Fig. 4 The incision for the arthrotomy can be seen here relative to the arthroscopic portals as well as the meniscal incision. This figure also demonstrates the passing of the nitinol suture passer to introduce the graft. The use of a needle driver and posterior retractor can help use the mobile window to aid in visualization of suture passage.

meniscocapsular sutures by protecting posterior neurovascular structures (►Fig. 4). The patella, patellar tendon, tibial plateau, and fibular head are valuable landmarks in marking out these incisions. The lateral collateral ligament and peroneal nerve are at risk in the posterolateral approach, while the medial collateral ligament saphenous nerve can be injured during a posteromedial approach. The ipsilateral gastrocnemius is elevated off the posterior knee capsule, and a retractor is placed anterior to it to protect the posterior neurovascular bundle. Anterior elevation of either the iliotibial band on the lateral side or sartorius fascia on the medial side allows for tying of the meniscal sutures below these structures and decreases the chances of soft tissue tethering.

Tibial Slot Preparation

Tibial slot preparation is performed following connection of the anterior and posterior horn insertions with a line using electrocautery. A 4.5-mm burr is then used to create a superficial reference slot along this line. This slot follows the native slope of the tibial plateau and should measure the same width and height as the burr. A hooked depth gauge is then used to measure the AP length of the tibial plateau and is also used as a reference for placement of a guide pin placed just distal and parallel to the reference slot (►Fig. 5). The pin is advanced to, but not through, the posterior tibial cortex and over-reamed with an 8 mm cannulated reamer. A box cutter is then used to create a tibial slot measuring 8 mm wide by 10 mm deep. A rasp is used to smooth and refine this slot to ensure smooth passage of the bony bridge on the meniscal allograft.

Graft Passage

Viewing of the recipient slot is performed through the ipsilateral portal while a zone-specific meniscal repair cannula is placed through the contralateral portal. The cannula is directed toward the junction of the posterior and middle thirds of the meniscus and a long, flexible nitinol suture-passing wire is passed to exit through the posterolateral or posteromedial safety incision. The proximal end of the pin is pulled out through the anterior arthrotomy and the PDS traction sutures from the allograft are passed through the

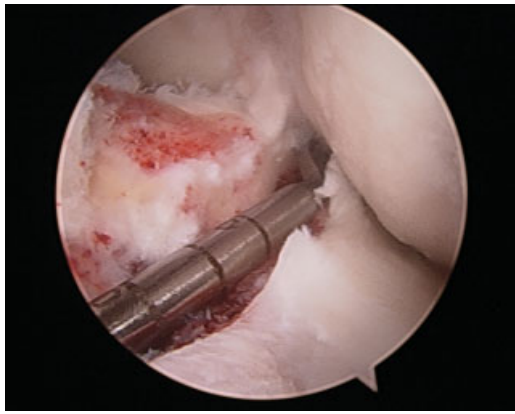


Fig. 5 The over-the-top guide is placed which can be used to ensure that the anteroposterior dimension of the meniscal graft is correct, as well as aid in guide pin placement for tunnel reaming.

loop of the nitinol wire. The wire and sutures are pulled through the posterior accessory incision and used to pull the meniscal allograft into the joint through the anterior arthrotomy (► **Fig. 6**). The bone bridge is advanced into the tibial slot and the meniscus is manually reduced under the ipsilateral femoral condyle with a finger placed through the arthrotomy. Varus or valgus stress may be required to open the ipsilateral compartment and aid with graft introduction in hyperflexion and reduction in hyperextension, typically done under arthroscopic visualization.

The knee is cycled to seat the graft after the meniscus is reduced and the bone block is secured in the tibial slot with a 7×23 mm bioabsorbable cortical interference screw in flexion under direct visualization. To accomplish this, a guidewire should be inserted between the bone bridge and the notch, and a tap is inserted over the guidewire to create a path for the screw. Using a freer and the side of an army-navy retractor, the posterior aspect of the bone plug is maintained in the trough during interference screw placement (► **Fig. 7**). The meniscus is then repaired to the capsule using inside-out vertical mattress sutures in the standard fashion (► **Fig. 8**). All-inside fixation devices may be placed posteriorly and outside-in techniques may be used anteriorly; however,

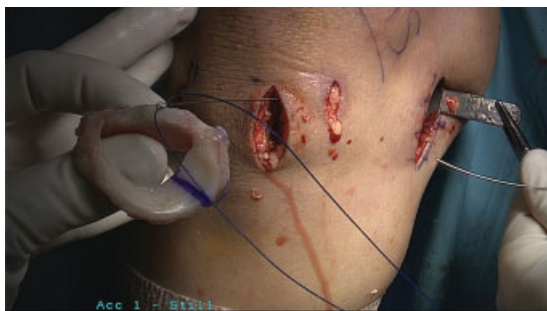

Fig. 6 Proper setup for the graft passage portion is crucial to ensure the graft is not damaged. The primary goal should be adequate placement of the osseous component with introduction of the soft tissue component into the anterior aspect of the compartment. This should be followed by arthroscopic visualization of the graft soft tissue reduction.

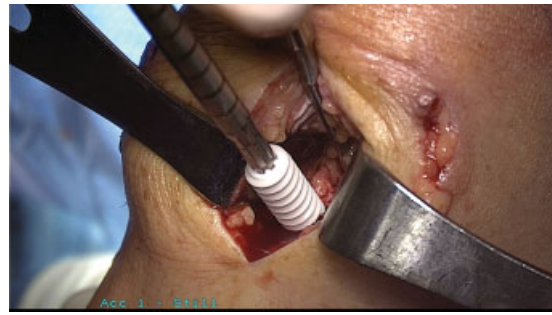


Fig. 7 Note the placement of the freer and army-navy to aid in the maintenance of the bone-block reduction during biocomposite screw placement.

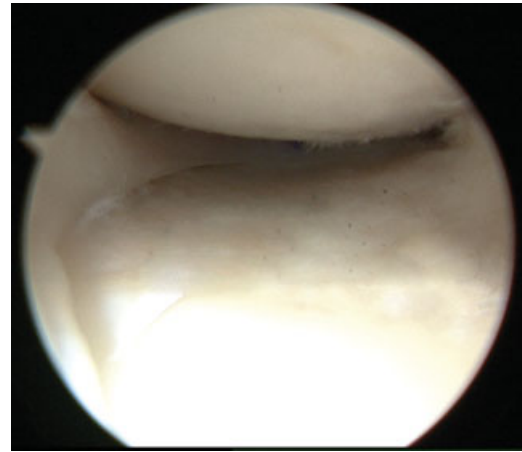


Fig. 8 After successful reduction, the meniscus should appear appropriately sized and placed in the anteroposterior dimension. Suture fixation follows typically alternating vertical mattress sutures superior and inferior to the graft.

this is typically not necessary with an adequate mobile window posteriorly. In general, 8 to 10 sutures are required. It is important to balance the meniscus using a combination of vertical mattress sutures both superior and inferior to the graft to decrease the amount of graft eversion. Incisions are then closed in the standard fashion, and the knee is immobilized in a hinged knee brace locked in extension. Radiographs are obtained at the first postoperative follow-up appointment.

Concurrent Procedures

Malalignment

If a concurrent high tibial osteotomy (HTO) is to be performed to correct coronal malalignment, all steps of the meniscus transplantation should be completed first. Opening wedge HTO is indicated in patients with medial meniscus deficiency and varus alignment. The opening wedge osteotomy should be performed such that osteotomy line passes 1.5 cm below the bottom of the tibial slot. Care should be taken when wedging open the osteotomy as the osteotomy can propagate up toward the tibial slot rather than laterally toward the fibular head. A distal femoral osteotomy (DFO) is indicated in the valgus knee with lateral meniscal deficiency, and as above,

all steps for meniscal transplantation should be completed before performing the osteotomy.

Anterior Cruciate Ligament Reconstruction

A modified bridge-in-slot technique is used if the need exists to reconstruct the ACL. Two smaller bone blocks are used instead of one long bridge to allow the ACL graft to pass between the blocks. A soft tissue graft should be used to allow for the smallest tibial tunnel as possible and avoid unseating the allograft blocks when passing the graft. The femoral and tibial tunnels for the ACL graft should be drilled first, and then the meniscal slot can be prepared in the usual fashion. The ACL graft is then passed and fixed on the femoral side before preparing the meniscal allograft. To prepare the transplant for insertion, the central third of the meniscal bone block is removed to create separate anterior and posterior bone blocks.

The ACL tibial aiming guide is then used to drill two transtibial tunnels that exit inside the prepared meniscal slot. The smallest available tibial reamer is used to ream over the guide pins. Two nonabsorbable sutures are then used to facilitate passage of the meniscal allograft by placing one through the anterior horn of the allograft and the other through the posterior horn. A suture passer is then used to pass these sutures through their respective tibial tunnels, and the graft is reduced, ensuring that both bony and soft tissue components are in appropriate position. The sutures are then tied over a bony bridge on the tibia and the tibial side of the ACL graft is fixed. To complete the procedure, the menisco-capsular sutures are placed and tied.

Treatment of Focal Chondral Defects

If required, autologous chondrocyte implantation (ACI) or osteochondral allografting should be performed following meniscal transplantation. The knee should be placed in flexion when performing an arthrotomy to access the defect and care should be taken to avoid injury to the anterior horn of the meniscal transplant when performing the arthrotomy.

Complications

Complications are similar to those encountered with meniscal repair and include infection, arthrofibrosis, incomplete healing of the sutured allograft to capsule, and saphenous or peroneal nerve injury. The transplanted meniscus is at higher risk for injury than the native meniscus, and tears are treated with repair or meniscectomy as they would be if encountered in the native meniscus.

Rehabilitation

For the first 2 postoperative weeks, patients are only allowed partial weightbearing on the affected knee with the hinged knee brace locked in extension. Range of motion is limited from 0 to 90 degrees and only allowed without bearing weight on the affected limb. From weeks 3 to 8, patients may progress to full weightbearing as tolerated and increase their non-weightbearing flexion to more than 90 degrees.

Full weightbearing and range of motion without the brace is allowed starting at 9 weeks and patients are progressed to

in-line running at 16 weeks. Return to full activity is permitted between 6 and 9 months if full pain-free motion has been achieved with a minimum of 80 to 85% strength as compared with the contralateral leg. Patients are discouraged from returning to cutting or pivoting sports due to the increased propensity of injury to the transplanted meniscus as compared with the native meniscus.

Clinical Evidence and Outcomes

It can be difficult to draw conclusions regarding the clinical outcomes following meniscal allograft transplantation (MAT). The literature is replete with both short-term and long-term studies following MAT, but the studies are extremely variable and difficult to draw comparisons from. Further, the majority of available studies are Level IV in nature, with no published randomized controlled trials, and thus the overall quality of the available evidence is low. Finally, many of the studies reporting on MAT outcomes contain patients who have undergone concomitant surgical procedures, including articular cartilage repair/restoration, realignment procedures, and/or ligament reconstruction, making it challenging to understand the relative contribution of the MAT. MAT procedures in the medial compartment are substantially different from those performed in the lateral compartment, and soft tissue procedures, bone plug techniques, and bridge-in-slot techniques are significantly different from one another. As such, careful analysis of the literature must be performed when attempting to extrapolate any reported results to any individual patient.

Recently, two systematic reviews^{20,21} were published that each report on clinical outcomes following MAT. Both published in 2011, these studies comprehensively discuss the available literature on MAT through its first two to three decades of clinical utilization. Hergan et al²¹ reviewed 14 articles each with a minimum follow-up of 2 years and included only those articles with documented bony fixation of the allograft meniscal horns. The authors concluded that in appropriate patients, MAT results in pain relief, improved function, and good patient outcomes. The authors also noted improved subjective and objective outcomes in patients without significant chondromalacia who underwent concomitant procedures to address articular cartilage disease, ligamentous instability, and/or malalignment. The authors found no difference between medial and lateral MAT procedures, and further, found no differences between patients undergoing isolated MAT and those undergoing MAT with concomitant procedures. In a separate review, Elattar et al²⁰ reviewed 44 articles with a total of 1,136 meniscal allografts (678 medial and 458 lateral) in 1,068 patients with a mean age of 35 years. This review consisted of trials with a minimum follow-up of 6 months and included studies over nearly three decades, resulting in significant heterogeneity in surgical technique among the included articles. The authors found that regardless of the 12 scoring systems and four imaging modalities used to assess outcomes, all studies noted clinical improvement postoperatively with complication and failure rates noted to be acceptable by all authors. Of note, the

average modified Coleman scores for these 44 studies was 44 ± 9 , indicating an overall low level of quality.

As discussed, meniscus transplantation is often performed concomitantly with articular cartilage procedures. A separate systematic review by Harris et al²² analyzed the clinical outcomes of “biologic knee reconstruction” by analyzing publications describing patients undergoing these combined procedures. In this review, the authors identified six studies with 110 patients undergoing combined MAT with either osteochondral autograft transfer (17), ACI (73), osteochondral allograft transfer (20), or microfracture (3). Several patients also underwent additional concomitant procedures, including ACL reconstruction (ACLR), HTO, DFO, collateral ligament reconstruction, and/or hardware removal from prior surgeries. At a mean follow-up of 36 months, the authors found improved clinical outcomes in all studies. Interestingly, the authors noted that in four studies, the outcomes of combined procedures were equivalent to those of either procedure performed in isolation, while in the other two studies, patients undergoing combined procedures performed worse. The rate of repeat surgery in this cohort was 50% (not necessarily associated with clinical failure), and the overall failure rate was 12%, with 85% of these due to failure of the MAT as opposed to the cartilage procedure.

A summary of many of these studies is provided in **Table 1**.²²⁻⁴⁹ Of note, in the largest study of MAT outcomes to date, McCormick et al⁵⁰ reported on the clinical outcomes of 172 patients who underwent MAT with a single surgeon, with an average follow-up of 59 months (minimum 24 months). Within this cohort, 40% underwent isolated MAT, with 60% undergoing MAT with concomitant procedures such as articular cartilage surgery, corrective osteotomies, and ligament reconstruction. Sixty-four patients (32% of the cohort) underwent subsequent surgery, of which arthroscopic debridement was performed in 38 and ultimately revision MAT or future arthroplasty was performed in eight patients (5%). Interestingly, patients who underwent secondary surgery within 2 years of the index MAT had an 8.4 odds ratio for future arthroplasty or MAT revision. Overall, this study suggests that MAT has an overall survival rate of 95% at an average 5-year follow-up, but that nearly one-third of patients requires subsequent surgery, and of those, patients requiring early surgery (within 2 years) are at a significantly higher risk of subsequent revision MAT or arthroplasty.

Several authors^{24,36} have reported on the outcomes of MAT in high-level athletes, with somewhat encouraging results. In 2014, Marcacci et al³⁶ published the clinical outcomes of 12 male professional soccer players undergoing MAT (6 medial and 6 lateral) after a prior subtotal meniscectomy. Seven patients underwent concomitant procedures at the time of MAT. In this cohort, an arthroscopic bone plug-free technique was used with a single tibial tunnel and “all-inside” meniscal sutures. At final follow-up 3 years postoperatively, 11 of the 12 patients had returned to soccer (92%), with 9 still competing as professionals, with an average time to return to soccer competition of 10.5 ± 2.6 months. Interestingly, the authors reported significant improvements in several outcomes scores (Tegner, Lysholm, International Knee Documen-

tation Committee [IKDC], WOMAC [Western Ontario and McMaster Osteoarthritis index], and visual analog scale) at 12 months, but there were no significant improvements in these scores at final follow-up. The one patient who did not return to soccer underwent a concomitant ACLR and unfortunately sustained an infection. Chalmers et al²⁴ reported on 13 high-level athletes (high school through professional level) with an average follow-up of 3.3 years. In this cohort, patients were treated either with a bridge-in-slot technique ($n = 10$) or a double bone plug technique ($n = 3$) to accommodate concomitant ACLR. Overall, 10 patients (77%) returned to play (9 of them reaching their desired level of play) with a mean time to return to sport of 17 months. The authors reported significant improvements in nearly all outcomes scales, including IKDC, Lysholm, knee injury and osteoarthritis outcome score, and satisfaction. Of note, no significant differences were noted in Tegner activity level, which went from an already high level of eight preoperatively to nine postoperatively. Overall, these two studies describe high rate of return to play in high-level athletes, but it is still unclear how these results may hold up over time. Furthermore, it is uncertain how these results may apply to patients who are extremely active, but at lower levels (“the weekend warrior”).

In a recent study comparing the clinical outcomes of patients undergoing medial MAT ($n = 56$) to those in patients undergoing lateral MAT ($n = 35$), Yoon et al⁴⁸ reported no significant differences in clinical outcomes between the groups, including range of motion, pain, IKDC scores, Lysholm scores, Tegner activity scores, and patient satisfaction. The authors also reported an increased rate of concomitant ACLR in the medial group and an increased rate of cartilage procedures in the lateral group. In addition, the authors did note that significantly more grafts were found to be extruded on MRI in the medial MAT group compared with the lateral MAT group, though follow-up MRI was only performed on 35 patients (11 medial and 24 lateral). However, the clinical relevance of this finding is unclear. Cole et al²⁵ performed a subgroup analysis of medial versus lateral MAT procedures in a cohort of 36 patients receiving a total of 40 allografts. The authors reported significant improvements in the overall cohort at a minimum 2-year follow-up. Although there were no significant differences between the medial and lateral groups, there was a trend in the lateral group toward greater clinical improvement. Farr et al²⁶ reported on the clinical outcomes of 29 patients undergoing MAT with concomitant ACI. Similar to the study by Cole et al,²⁵ the authors reported significant improvements in symptoms and function in patients undergoing MAT, with no significant differences between the medial and lateral groups upon subgroup analysis. In contrast to the study by Cole et al, however, the authors reported a higher improvement in Lysholm score in the medial group (improved by 29 points) compared with the lateral group (improved by 1 point). Because of the heterogeneity of these patient populations, including the differences in concomitant procedures performed in each study and within each of the individual study's cohorts, it is difficult to draw conclusions as to whether medial or lateral MAT procedures do better than the other. Other authors, including

Table 1 Selected MAT outcomes

Author	Patients no. (grafts no.)	Medial	Lateral	Mean age (y)	Mean f/u (min) (mo)	Graft preservation technique	Fixation (if not stated m/L)	Fixation medial	Fixation lateral	Sizing method	Concomitant procedures	Subjective outcomes	Objective (imaging) outcomes	Summary of outcomes	Failures, complications
Marcacci et al, 2014 ³⁶	12 (12)	6	6	25	36 (36)	FF nonirradiated	Arthroscopic; all suture			Radiographs	2 ACLR, 3 MFX, 1 chondrocyte harvesting, 1 OC scaffolding	Tegner 8-10, Lysholm 67-92, IKDC 62-85, WOMAC 77-92	Not provided	11/12 professional soccer players returned to play, with 9 (75%) at the professional level at 3 y	1 infection (8%); 3 (25%) with second surgeries not related to MAT and considered successes
Yoon et al, 2014 ⁴⁸	91 (91)	35	56	34	40 (24)	FF		Bone plug	Keyhole	MRIs	Medial: 18 ACLR, 10 ACI, 4 MFX, 2 HTO; lateral: 11 ACLR, 2 PCL, 11 ACI, 12 MFX	VAS 5-3, IKDC 52-67, Lysholm 64-77, Tegner 2-4	Increased extrusion in medial compared with lateral on f/u MRI	No differences between medial and lateral: isolated MAT group with higher VAS and Lysholm than combined group	Unclear, but 27 second look scopes for "painful knee with suspected meniscal tear"
Jang and Wang, 2013 ³⁹	13 (13)	0	13	33	21 (13)	Not provided			Arthroscopic; all inside suture keyhole tunnel with bone bridge	n/a	5 MFX	Lysholm 85, IKDC 80, Tegner 6; all significantly improved	Not provided	This "novel" technique is safe and effective for lateral MAT	None
Roumazelle et al, 2013 ³⁸	22 (22)	2	20	37	53 (SD 19)	FF nonirradiated	Arthroscopic; two tibia tunnels without bone plugs			Pollard	5 ACLR	Significant improvements in KOOS, IKDC	MRI with 17/19 grafts extruded, with 2 totally extruded; MRI signal heterogeneous in 14/19	MAT without bone plugs is effective, and the graft heals in "most" cases at 6 mo	No revisions, 2 second look scopes
Kim et al, 2012 ³¹	106 (110)	27	83	33	49 (24)	Cryo for 5, FF for 105		Trough x3, keyhole x9, boneplug x15	Trough x2, keyhole x81	n/a	Unclear ²² ACLR, 4 OCD, 1 ACI/PLC, 1 PCL	Lysholm 73-92, KSS pain score 33-48	Using clinical outcome, MRI, and arthroscopy; 82% satisfactory, 7% fair, 11% poor	MAT with bone fixation is effective; the authors recommend MRI or arthroscopy to evaluate outcomes in addition to clinical assessment	11% with poor outcomes (failures)
Marcacci et al, 2012 ²⁷	32 (32)	16	16	36	40 (36)	FF nonirradiated	Arthroscopic; all inside all suture			MRI and XR	4 ACLR, 3 HTO, 3 DFO	Significant improvements in VAS, SE36, Tegner, Lysholm, IKDC	MRI with 69 extruded grafts, no clinical correlation	No differences between medial and lateral: no differences between isolated MAT and combined MAT	2 (6%), due to lack of benefit

Table 1 (Continued)

Author	Patients no. (grafts no.)	Medial	Lateral	Mean age (y)	Mean f/u (min) (mo)	Graft preservation technique	Fixation (if not stated m/L)	Fixation medial	Fixation lateral	Sizing method	Concomitant procedures	Subjective outcomes	Objective (imaging) outcomes	Summary of outcomes	Failures, complications
Saltzman et al. 2012 ²¹	22 (22)	13	9	33	108 (74)	FF	10 bridge in slot, 3 double bone plug	12 double bone plug, 1 bridge in slot	5 keyhole, 4 bridge in slot	Pollard	5 ACL, 3 ACL revision, 2 MFX, 4 osteochondral autograft/allograft, 3 ROH, 1 thermal shrinkage	86% near-normal or normal IKDC	Not provided	Survivorship 88%; all patients completely or mostly satisfied	12% failures
Chalmers et al. 2013 ²⁴	13 (13)	3	10	19	40 (23)	FF nonirradiated	10 bridge in slot, 3 double bone plug			Pollard	3 ACLR, 3 OA graft, 1 DFO, 1 MFX	KOOS 76, IKDC 77, Lysholm 81	Not provided	High level athletes with symptomatic "postmeniscectomy" syndrome can return to desired level of play	3 (23%) needing further surgery including 1 rMAT, 1 MXR, 1 MX
Ha et al. 2011 ²⁸	22 (22)	22	0	36	25 (12)	FF	Modified bone plug			Pollard	2 osteotomy, 15 ACLR, 2 PCL, 4 PLC	Lysholm 68 to 90, IKDC 60 to 85	Mean graft extrusion was 4 mm, and arthrosis progression (on MRI) was observed in 22%	MAT with modified bone plug method is effective; meniscal extrusion not correlated with clinical outcomes	1 case of posterior root graft "failure" on postoperative MRI and second look arthroscopy
Kim et al. 2011 ³⁰	29 (29)	0	29	30	54 (24)	2 cryo, 27 FF	2 trough, 27 keyhole			Pollard	None	Lysholm 70-90, HSS 15-27; 69% satisfactory, 17% fair, 14% poor	Postop MRI in 22 knees, revealed 4 gross and 5 small allograft tears, mean extrusion 4mm	Acceptable subjective and objective findings at short-term intermediate follow-up	14% (4 cases)
Lee et al. 2011 ³⁵	43 (43)	6	37	36	32 (2.3)	n/a	Modified double bone plug			n/a	n/a	Lysholm 72-88, but not related to signal intensity on MRI	MRI signal intensity increased over time, and was higher for the anterior horn compared with posterior horn	Transplanted menisci have higher MRI signal intensity than native menisci; signal intensity on MRI not related to clinical outcome	2% with fair outcomes on Lysholm; no failures or complications
Zhang et al. 2012 ⁴⁹	18 (18)	7	11	37	25 (18)	Deep frozen, low dose (1.5 Mrad) irradiation		Double bone plug	9 double bone plug, 2 bone bridge	Pollard XR and MRI	10 (ACLR, osteotomies)	Significant improvements in Lysholm, KOOS, VAS	67% completely or mostly satisfied	No differences between medial/lateral; no differences between isolated/combined	11% (n = 2)
González-Lucena et al. 2010 ²⁷	33 (33)	14	19	39	78 (63)	FF nonirradiated	Arthroscopic; all inside all suture			Pollard	8 ACLR, 8 MFX, 9 chondral shaving	Lysholm 65-89, with 69% of scores good or excellent; Tegner	MRI with extrusion in all cases, with a mean of 36% of total meniscal size	No differences between lateral/medial; no differences	33% complication rate

(Continued)

Table 1 (Continued)

Author	Patients no. (grafts no.)	Medial	Lateral	Mean age (y)	Mean f/u (min) (mo)	Graft preservation technique	Fixation (if not stated mL)	Fixation medial	Fixation lateral	Sizing method	Concomitant procedures	Subjective outcomes	Objective (imaging) outcomes	Summary of outcomes	Failures, complications
LaPrade et al, 2010 ³³	40 (4)	19	21	25	30 (22)	Deep frozen nonirradiated		Bone plugs	Bone trough	Plain radiographs	6 ACLR, 4 revision ACLR, 4 ROH, 5 MFx, 3 OA allo-graft, 3 DFO	IKDC 55-72, Cincinnati 55-75	Not provided	35/40 (88%) successful, 91% improved pain and function	5 with retears requiring partial meniscectomy; 1 infection
Lee et al, 2010 ³⁴	43 (43)	7	36	34	61 (42)	FF		Double bone plug	Keyhole	Plain radiographs	n/a	Lysholm 72-92	Mean graft extrusion (MRI at 1 y) was 3 mm, with 60% of knees "nonextruded" and 50% of knees "extruded"	No correlation of graft extrusion with Lysholm score improvement	
Rue et al, 2008 ³⁹	30 (31)	20	11	30	37 (23)	Cryo (before 2004) and FF (after 2004)		Double bone plug (14, before July 2005), then bridge in slot (6, after July 2005)	Keyhole (4, before July 2005), then bridge in slot (7, after July 2005)	n/a	16 ACL, 15 OATS	48% normal/near-normal IKDC	Not provided	76% mostly or completely satisfied, 90% would repeat surgery	2/29 at 2.4 and 3 y
Bhosale et al, 2007 ²³	8 (8)	2	6	42	38 (24)	Cryo	Bone plugs			n/a	8 ACL (6 bipolar)	Lysholm 49-64	MRI with "good" integration of menisci with the capsule, mild extrusion in 1, no rejection	63% satisfied; combination of ACL with MAT is effective	35% in first 2 y
Farr et al, 2007 ²⁶	29 (29)	21	8	37	52 (38)	FF	Bridge in slot			Pollard	29 ACL (4 bipolar), 6 HTO, 1 TT medialization, 1 TTO with ACL, 7 ACLR, 1 AMZ	Lysholm 58-78, Cincinnati 4-6; no differences medial vs. lateral, isolated vs. concomitant, unipolar vs. bipolar	40% good to excellent, including 4 early failures; overall MAT with ACL results in improved symptoms and knee function, but these improvements were less than literature reported outcomes with isolated procedures	4/33 in first 2 y	
Hommen et al, 2007 ⁵⁵	22 (22)	14	8	32	141 (115)	Cryo		3 double bone plug, 8 all suture, 1 single posterior bone plug	2 single bone plug with trough, 5 all suture, 1 double bone plug	Pollard	Multiple	90% improvement in Lysholm and pain scores, with no difference between medial and	On MRI, all allografts with shrinkage and five with Grade III signal intensities	30% good to excellent, 2 worse (both lateral)	7/20 total failures (as determined by Lysholm and pain scores); 55% failure rate if also considering MRI, second look surgery, and surveys

Table 1 (Continued)

Author	Patients no. (grafts no.)	Medial	Lateral	Mean age (y)	Mean f/u (min) (mo)	Graft preservation technique	Fixation (if not stated ml/l)	Fixation medial	Fixation lateral	Sizing method	Concomitant procedures	Subjective outcomes	Objective (imaging) outcomes	Summary of outcomes	Failures, complications
Cole et al, 2006 ²⁵	40 (40)	25	15	31	34 (24)	> 80% cryo, < 20% nonirradiated FF		Double bone plug	Keyhole	Pollard	6 osteochondral allograft/allograft, 2 MFx, 2 OCD fixation, 1 ACL, 1 chondral debridement, 6 ligament reconstruction, 1 osteotomy	Significant improvements in Lysholm, Tegner, Noyes, IKDC	Not provided	78% mostly or completely satisfied, 88% of successes would repeat surgery	7 of 43
Rueff et al, 2006 ⁴⁰	8 (8)	8	0	51	65 (60)	Cryo	1 double bone plug, 7 bone bridge			n/a	All with ACLR	IKDC improved from 61 to 90, Lysholm significantly improved	Not provided	88% would repeat procedure	None reported
Sekiya et al, 2006 ⁴³	25 (25)	0	25	30	39 (66)	Cryo	12 bone bridge, 8 suture only, 5 bone plugs			Pollard, Shaifer	None	SF36 higher than age/sex matched controls; 96% improved function and activity level; bony fixation with better ROM compared with suture fixation	Not provided	Isolated lateral MFAT is a beneficial procedure in properly selected patients; bony fixation may have benefit over suture fixation	Not defined, 1/25 unsatisfied
Noyes et al, 2005 ³⁶	38 (40)	20	20	30	40 (n/a)	Cryo		Double bone plug	Bone block	Pollard	16 osteochondral autograft, 7 ACLR, 1 MCLR, 1 PCL, 1 ACL/PCL	89% pain free with ADLS	Meniscal allograft characteristics normal in 43%, altered in 30%, failed in 11% (modality unclear)	MAT improves short-term function and decreases knee pain	11 (28%) failed, lateral at mean 53 mo, medial at mean 25 mo
Verdonk et al, 2005 ⁵⁷	100 (100)	39	61	35	86 (24)	Allografts in culture for 2 wk (Dulbecco modified eagle medium) supplemented with 20% autologous serum	All suture, no bone plugs			n/a	3 ACLR, 15 HTO, 2 DFO, 4 OA transfer, 3 MFx	Significant improvements in modified HSS scores	Not provided	74% medial, 70% lateral survived, increased survival when osteotomy performed	21 failed grafts (11 medial, 10 lateral)
Graf et al, 2004 ⁵⁸	8 (8)	8	0	33	115 (96)	Cryo (7/8 irradiated)	Bone block			Pollard	All ACLR (staged or concomitant)	100% of patients were satisfied; no normal IKDC scores; 1 nearly normal, 4 abnormal, 3 severely abnormal	Not provided	Medial MAT with ACLR can significantly improve knee function in ligamentously unstable, medial meniscus	1/9 in first 2 y (due to low grade infection vs. immune reaction)

(Continued)

Table 1 (Continued)

Author	Patients no. (grafts no.)	Medial	Lateral	Mean age (y)	Mean f/u (min) (mo)	Graft preservation technique	Fixation (if not stated m/L)	Fixation medial	Fixation lateral	Sizing method	Concomitant procedures	Subjective outcomes	Objective (imaging) outcomes	Summary of outcomes	Failures, complications
Sekiya et al., 2003 ⁴²	28 (31)	7	24	35	32 (20)	Cryo		Transosseous bone tunnels	Bone bridge	Shaffer	19 ACLR, 9 re-vaACL, 2 lateral closing wedge HTO	93% somewhat or greatly improved; 86% normal or normal IKDC with SF36 components higher than age-sex matched populations	Not provided	MAT with ACLR can be beneficial in properly selected patients with ACL and meniscal deficiency	1 patient felt worse
Yoldas et al., 2003 ⁴⁶	31 (34)	19	15	28	33 (13)	FF		Bone plugs	Bone bridge	"Similar" to Pollard	20 ACLR (12 primary, 8 revision)			97% somewhat or greatly improved, 97% knee function near normal or normal	
Ryu et al., 2002 ³¹	25 (26)	10	16	35	33 (12)	Not provided		Bone blocks	Bone bridge	n/a	12 ACLR	83% satisfied; significant improvements in IKDC, Lysholm	10 patients underwent second look scope; 5 normal grafts, 3 with shrinkage, 2 with recurrent tears	MAT improves early- and mid-term function and decreases knee pain; isolated MAT and MAT with ACLR with similar outcomes	No complications, 1 clinical failure
Rath et al., 2001 ³⁹	18 (22)	15	7	30	52 (24)	Deep frozen and cryo		Double bone plug	Bone block	Pollard XR and Shuffler MRI	11 ACLR, 3 mix of opposite compartment meniscus, 1 AMZ	Mean IKDC 54, significant improvement in SF36, including improved scores in patients who re-tear store allograft	MRI not provided	14/22 (64%) successful	8/26 with symptomatic re-tear at mean 31 mo, resulting in 6 partial and 2 total meniscectomies (4 of these patients had concomitant ACLR, with ACL intact at the time of second arthroscopy)
Stollsteimer et al., 2000 ⁴⁴	22 (23)	11	12	31	40 (24)	Cryo	Bone plugs		AP/lateral XR	n/a		Overall reduction of pain; significant improvements in Tegner, IKDC, and Lysholm	Bilateral MRI in 12/22 patients, with allograft an average 63% of the normal meniscus size	78% with pain improvement, but allograft shrinkage on MRI remains a concern	Not defined

Abbreviations: ACLR, anterior cruciate ligament reconstruction; ACI, autologous chondrocyte implantation; AMZ, anteromedialization; AP, anteroposterior; DFO, distal femoral osteotomy; FF, fresh frozen; f/u, follow-up; HSS, hospital for special surgery score; HTO, high tibial osteotomy; IKDC, international knee documentation committee; KOOS, knee injury and osteoarthritis outcome score; MFx, microfracture; MAT, meniscal allograft transplantation; MRI, magnetic resonance imaging; MXR, meniscus repair; MX, meniscectomy; n/a, data not available; OA, osteochondral allograft; OATS, osteochondral autograft transfer system; OCD, osteochondritis dissecans; PCL, posterior cruciate ligament; PLC, posterolateral corner; ROH, removal of hardware; rMAT, revision meniscal allograft transplantation; TT, trans tibial; TTO, tibial tubercle osteotomy; ROM, range of motion; VAS, visual analog scale; XR, X-ray.

^aUnclear (all treated either at same time of MAT or during separate operation).

Rue et al,³⁹ Ryu et al,⁵¹ Stollsteimer et al,⁴⁴ and Yoldas et al,⁴⁶ have also shown no difference in outcomes between medial and lateral MAT procedures.

In another study, De Coninck et al⁵² similarly reported on the imaging findings of meniscal allografts by comparing patients undergoing arthroscopic MAT with bone tunnel ($n = 21$: 7 medial and 14 lateral) to those undergoing open MAT with soft tissue ($n = 16$: 6 medial and 10 lateral). The authors found significantly more radial displacement in the open group compared with the arthroscopic group, but the clinical relevance of radial displacement remains unclear. Other authors have attempted to correlate objective outcomes, such as extrusion on MRI, with clinical outcomes. Lee et al⁵³ reported on 31 patients undergoing MAT and followed postoperatively both with serial MRI studies and with clinical outcomes scales. In a cohort of 31 patients (9 medial and 22 lateral), the authors reported substantial allograft mid-body shrinkage that occurred progressively for 1 year in 16% of patients, with no correlation in Tegner or Lysholm outcomes scores at 1 and 2 years. In addition, the authors found no correlation with preoperative alignment, cartilage integrity, age, gender, or amount of graft extrusion with the amount of graft shrinkage. Ha et al⁵⁴ also looked at the correlation of MRI findings with clinical outcomes in patients undergoing MAT. In this study, 36 patients (15 medial and 21 lateral) were evaluated at an average of 31 months postoperatively (minimum 24 months). At final follow-up, the authors reported an average meniscal extrusion of 3.9 ± 1.9 mm with a relative percentage extrusion of $42.1 \pm 17.7\%$. Seven cases had minor extrusion (< 3 mm), 27 cases had major extrusion (> 3 mm), and 2 cases had no extrusion. The authors reported significant improvements in Lysholm knee scores (61–88, $p < 0.001$) and reported no correlation between meniscal extrusion and clinical outcome measures. Similar to the aforementioned study conducted by Yoon et al,⁴⁸ the findings from these studies indicate that it can be difficult to translate imaging results in post-MAT patients to clinical outcomes.

Overall, clinical outcomes following MAT, whether performed in isolation or performed with concomitant articular cartilage, realignment, or soft tissue reconstruction procedures are acceptable with the majority of studies reporting improved clinical outcomes regardless of the scoring system employed. Although the definition of MAT failure is certainly variable by study, the overall failure rates when using end points such as graft destruction/removal, revision MAT, and/or conversion to arthroplasty can be estimated at 10 to 20% at an average 4.6 years following surgery (range, 8 months–20 years).^{20,21} This number certainly increases if considering the need for secondary surgery or the appearance of an extruded graft on MRI as indicators of failure. As mentioned above, there are no discernable clinical or radiographic differences between patients undergoing medial MAT versus lateral MAT. In addition, there are no significant differences in outcomes between patients undergoing isolated MAT versus MAT performed with concomitant procedures. Finally, no differences could be found between the various fixation methods

(e.g., all-arthroscopic, bridge-in-slot, bone trough, double bone plug, etc.).

Conclusion

MAT has proven to be a safe and effective technique in reducing pain and improving function in the symptomatic meniscal deficient knee. Controversy exists with regard to appropriate sizing methods, processing/sterilization techniques, and surgical technique. Nonetheless, the procedure has been proven to provide good clinical results at short- to intermediate-term follow-up. Evaluation of long-term clinical outcomes is necessary, as is evaluation of meniscal replacement alternatives including bioactive scaffolds, synthetic implants, and tissue-engineered menisci.

References

- 1 Baratz ME, Fu FH, Mengato R. Meniscal tears: the effect of meniscectomy and of repair on intraarticular contact areas and stress in the human knee. A preliminary report. *Am J Sports Med* 1986;14(4):270–275
- 2 Allen PR, Denham RA, Swan AV. Late degenerative changes after meniscectomy. Factors affecting the knee after operation. *J Bone Joint Surg Br* 1984;66(5):666–671
- 3 Yoon KH, Lee SH, Bae DK, Park SY, Oh H. Does varus alignment increase after medial meniscectomy? *Knee Surg Sports Traumatol Arthrosc* 2013;21(9):2131–2136
- 4 Chatain F, Robinson AH, Adeleine P, Chambat P, Neyret P. The natural history of the knee following arthroscopic medial meniscectomy. *Knee Surg Sports Traumatol Arthrosc* 2001;9(1):15–18
- 5 Voloshin AS, Wosk J. Shock absorption of meniscectomized and painful knees: a comparative in vivo study. *J Biomed Eng* 1983; 5(2):157–161
- 6 MacConaill MA. The movements of bones and joints; the synovial fluid and its assistants. *J Bone Joint Surg Br* 1950;32-B(2):244–252
- 7 Renström P, Johnson RJ. Anatomy and biomechanics of the menisci. *Clin Sports Med* 1990;9(3):523–538
- 8 Walker PS, Erkman MJ. The role of the menisci in force transmission across the knee. *Clin Orthop Relat Res* 1975;(109): 184–192
- 9 Markolf KL, Mensch JS, Amstutz HC. Stiffness and laxity of the knee—the contributions of the supporting structures. A quantitative in vitro study. *J Bone Joint Surg Am* 1976;58(5):583–594
- 10 McDevitt CA, Webber RJ. The ultrastructure and biochemistry of meniscal cartilage. *Clin Orthop Relat Res* 1990;(252):8–18
- 11 Meredith DS, Losina E, Mahomed NN, Wright J, Katz JN. Factors predicting functional and radiographic outcomes after arthroscopic partial meniscectomy: a review of the literature. *Arthroscopy* 2005;21(2):211–223
- 12 Arnoczky SP, Warren RF, McDevitt CA. Meniscal replacement using a cryopreserved allograft. An experimental study in the dog. *Clin Orthop Relat Res* 1990;(252):121–128
- 13 Jackson DW, Whelan J, Simon TM. Cell survival after transplantation of fresh meniscal allografts. DNA probe analysis in a goat model. *Am J Sports Med* 1993;21(4):540–550
- 14 Szomor ZL, Martin TE, Bonar F, Murrell GA. The protective effects of meniscal transplantation on cartilage. An experimental study in sheep. *J Bone Joint Surg Am* 2000;82(1):80–88
- 15 Dienst M, Greis PE, Ellis BJ, Bachus KN, Burks RT. Effect of lateral meniscal allograft sizing on contact mechanics of the lateral tibial plateau: an experimental study in human cadaveric knee joints. *Am J Sports Med* 2007;35(1):34–42

- 16 Prodomos CC, Joyce BT, Keller BL, Murphy BJ, Shi K. Magnetic resonance imaging measurement of the contralateral normal meniscus is a more accurate method of determining meniscal allograft size than radiographic measurement of the recipient tibial plateau. *Arthroscopy* 2007;23(11):1174–1179, e1
- 17 Stone KR, Freyer A, Turek T, Walgenbach AW, Wadhwa S, Crues J. Meniscal sizing based on gender, height, and weight. *Arthroscopy* 2007;23(5):503–508
- 18 Van Thiel GS, Verma N, Yanke A, Basu S, Farr J, Cole B. Meniscal allograft size can be predicted by height, weight, and gender. *Arthroscopy* 2009;25(7):722–727
- 19 Bursac P, York A, Kuznia P, Brown LM, Arnoczky SP. Influence of donor age on the biomechanical and biochemical properties of human meniscal allografts. *Am J Sports Med* 2009;37(5):884–889
- 20 Elattar M, Dhollander A, Verdonk R, Almqvist KF, Verdonk P. Twenty-six years of meniscal allograft transplantation: is it still experimental? A meta-analysis of 44 trials. *Knee Surg Sports Traumatol Arthrosc* 2011;19(2):147–157
- 21 Hergan D, Thut D, Sherman O, Day MS. Meniscal allograft transplantation. *Arthroscopy* 2011;27(1):101–112
- 22 Harris JD, Cavo M, Brophy R, Siston R, Flanigan D. Biological knee reconstruction: a systematic review of combined meniscal allograft transplantation and cartilage repair or restoration. *Arthroscopy* 2011;27(3):409–418
- 23 Bhosale AM, Myint P, Roberts S, et al. Combined autologous chondrocyte implantation and allogenic meniscus transplantation: a biological knee replacement. *Knee* 2007;14(5):361–368
- 24 Chalmers PN, Karas V, Sherman SL, Cole BJ. Return to high-level sport after meniscal allograft transplantation. *Arthroscopy* 2013;29(3):539–544
- 25 Cole BJ, Dennis MG, Lee SJ, et al. Prospective evaluation of allograft meniscus transplantation: a minimum 2-year follow-up. *Am J Sports Med* 2006;34(6):919–927
- 26 Farr J, Rawal A, Marberry KM. Concomitant meniscal allograft transplantation and autologous chondrocyte implantation: minimum 2-year follow-up. *Am J Sports Med* 2007;35(9):1459–1466
- 27 González-Lucena G, Gelber PE, Pelfort X, Tey M, Monllau JC. Meniscal allograft transplantation without bone blocks: a 5- to 8-year follow-up of 33 patients. *Arthroscopy* 2010;26(12):1633–1640
- 28 Ha JK, Sung JH, Shim JC, Seo JG, Kim JG. Medial meniscus allograft transplantation using a modified bone plug technique: clinical, radiologic, and arthroscopic results. *Arthroscopy* 2011;27(7):944–950
- 29 Jang K-M, Wang JH. Lateral meniscus allograft transplantation using a single-incision technique. *Knee Surg Sports Traumatol Arthrosc* 2013; March 3 (Epub ahead of print)
- 30 Kim C-W, Kim J-M, Lee S-H, et al. Results of isolated lateral meniscus allograft transplantation: focus on objective evaluations with magnetic resonance imaging. *Am J Sports Med* 2011;39(9):1960–1967
- 31 Kim J-M, Lee B-S, Kim K-H, Kim K-A, Bin S-I. Results of meniscus allograft transplantation using bone fixation: 110 cases with objective evaluation. *Am J Sports Med* 2012;40(5):1027–1034
- 32 Kon E, Filardo G, Berruto M, et al. Articular cartilage treatment in high-level male soccer players: a prospective comparative study of arthroscopic second-generation autologous chondrocyte implantation versus microfracture. *Am J Sports Med* 2011;39(12):2549–2557
- 33 LaPrade RF, Wills NJ, Spiridonov SI, Perkinson S. A prospective outcomes study of meniscal allograft transplantation. *Am J Sports Med* 2010;38(9):1804–1812
- 34 Lee D-H, Kim S-B, Kim T-H, Cha E-J, Bin S-I. Midterm outcomes after meniscal allograft transplantation: comparison of cases with extrusion versus without extrusion. *Am J Sports Med* 2010;38(2):247–254
- 35 Lee D-H, Lee B-S, Chung J-W, et al. Changes in magnetic resonance imaging signal intensity of transplanted meniscus allografts are not associated with clinical outcomes. *Arthroscopy* 2011;27(9):1211–1218
- 36 Marcacci M, Marcheggiani Muccioli GM, Grassi A, et al. Arthroscopic meniscus allograft transplantation in male professional soccer players: a 36-month follow-up study. *Am J Sports Med* 2014;42(2):382–388
- 37 Marcacci M, Zaffagnini S, Marcheggiani Muccioli GM, et al. Meniscal allograft transplantation without bone plugs: a 3-year minimum follow-up study. *Am J Sports Med* 2012;40(2):395–403
- 38 Roumzeille T, Klouche S, Rousselin B, et al. Arthroscopic meniscal allograft transplantation with two tibia tunnels without bone plugs: evaluation of healing on MR arthrography and functional outcomes. *Knee Surg Sports Traumatol Arthrosc* 2013; March 19 (Epub ahead of print)
- 39 Rue J-PH, Yanke AB, Busam ML, McNickle AG, Cole BJ. Prospective evaluation of concurrent meniscus transplantation and articular cartilage repair: minimum 2-year follow-up. *Am J Sports Med* 2008;36(9):1770–1778
- 40 Rueff D, Nyland J, Kocabay Y, Chang HC, Caborn DNM. Self-reported patient outcomes at a minimum of 5 years after allograft anterior cruciate ligament reconstruction with or without medial meniscus transplantation: an age-, sex-, and activity level-matched comparison in patients aged approximately 50 years. *Arthroscopy* 2006;22(10):1053–1062
- 41 Saltzman BM, Bajaj S, Salata M, et al. Prospective long-term evaluation of meniscal allograft transplantation procedure: a minimum of 7-year follow-up. *J Knee Surg* 2012;25(2):165–175
- 42 Sekiya JK, Giffin JR, Irrgang JJ, Fu FH, Harner CD. Clinical outcomes after combined meniscal allograft transplantation and anterior cruciate ligament reconstruction. *Am J Sports Med* 2003;31(6):896–906
- 43 Sekiya JK, West RV, Groff YJ, Irrgang JJ, Fu FH, Harner CD. Clinical outcomes following isolated lateral meniscal allograft transplantation. *Arthroscopy* 2006;22(7):771–780
- 44 Stollsteimer GT, Shelton WR, Dukes A, Bomboy AL. Meniscal allograft transplantation: a 1- to 5-year follow-up of 22 patients. *Arthroscopy* 2000;16(4):343–347
- 45 Vundelinckx B, Bellemans J, Vanlauwe J. Arthroscopically assisted meniscal allograft transplantation in the knee: a medium-term subjective, clinical, and radiographical outcome evaluation. *Am J Sports Med* 2010;38(11):2240–2247
- 46 Yoldas EA, Sekiya JK, Irrgang JJ, Fu FH, Harner CD. Arthroscopically assisted meniscal allograft transplantation with and without combined anterior cruciate ligament reconstruction. *Knee Surg Sports Traumatol Arthrosc* 2003;11(3):173–182
- 47 Yoon J-R, Kim T-S, Lee Y-M, Jang H-W, Kim Y-C, Yang J-H. Transpatellar approach in lateral meniscal allograft transplantation using the keyhole method: can we prevent graft extrusion? *Knee Surg Sports Traumatol Arthrosc* 2011;19(2):214–217
- 48 Yoon KH, Lee SH, Park SY, Kim HJ, Chung KY. Meniscus allograft transplantation: a comparison of medial and lateral procedures. *Am J Sports Med* 2014;42(1):200–207
- 49 Zhang H, Liu X, Wei Y, et al. Meniscal allograft transplantation in isolated and combined surgery. *Knee Surg Sports Traumatol Arthrosc* 2012;20(2):281–289
- 50 McCormick F, Harris JD, Abrams GD, et al. Survival and Reoperation Rates After Meniscal Allograft Transplantation: Analysis of Failures for 172 Consecutive Transplants at a Minimum 2-Year Follow-up. *Am J Sports Med* 2014;42(4):892–897
- 51 Ryu RKN, Dunbar V WH, Morse GG. Meniscal allograft replacement: a 1-year to 6-year experience. *Arthroscopy* 2002;18(9):989–994
- 52 De Coninck T, Huysse W, Verdonk R, Verstraete K, Verdonk P. Open versus arthroscopic meniscus allograft transplantation: magnetic resonance imaging study of meniscal radial displacement. *Arthroscopy* 2013;29(3):514–521
- 53 Lee B-S, Chung J-W, Kim J-M, Cho W-J, Kim K-A, Bin S-I. Morphologic changes in fresh-frozen meniscus allografts over 1 year: a

- prospective magnetic resonance imaging study on the width and thickness of transplants. *Am J Sports Med* 2012;40(6):1384–1391
- 54 Ha JK, Shim JC, Kim DW, Lee YS, Ra HJ, Kim JG. Relationship between meniscal extrusion and various clinical findings after meniscus allograft transplantation. *Am J Sports Med* 2010;38(12):2448–2455
- 55 Hommen JP, Applegate GR, Del Pizzo W. Meniscus allograft transplantation: ten-year results of cryopreserved allografts. *Arthroscopy* 2007;23(4):388–393
- 56 Noyes FR, Barber-Westin SD, Rankin M. Meniscal transplantation in symptomatic patients less than fifty years old. *J Bone Joint Surg Am* 2005;87(Pt 2, Suppl 1):149–165
- 57 Verdonk PC, Demurie A, Almqvist KF, Veys EM, Verbruggen G, Verdonk R. Transplantation of viable meniscal allograft. Survivorship analysis and clinical outcome of one hundred cases. *J Bone Joint Surg Am* 2005;87(4):715–724
- 58 Graf KW Jr, Sekiya JK, Wojtys EM; Department of Orthopaedic Surgery, University of Michigan Medical Center, Ann Arbor, Michigan, USA. Long-term results after combined medial meniscal allograft transplantation and anterior cruciate ligament reconstruction: minimum 8.5-year follow-up study. *Arthroscopy* 2004;20(2):129–140
- 59 Rath E, Richmond JC, Yassir W, Albright JD, Gundogan F. Meniscal allograft transplantation. Two- to eight-year results. *Am J Sports Med* 2001;29(4):410–414